
Photo Quiz

Painful Red Eye

MOHENISH SINGH, LT, MC, USN, and ADAM SANBORN LT, MC, USN, *Naval Hospital, Jacksonville, Florida*

The editors of *AFP* welcome submissions for Photo Quiz. Guidelines for preparing and submitting a Photo Quiz manuscript can be found in the Authors' Guide at <http://www.aafp.org/afp/photoquizinfo>. To be considered for publication, submissions must meet these guidelines. E-mail submissions to afpphoto@aafp.org. Contributing editor for Photo Quiz is John E. Delzell, Jr., MD, MSPH.

A collection of Photo Quizzes published in *AFP* is available at <http://www.aafp.org/afp/photoquiz>.

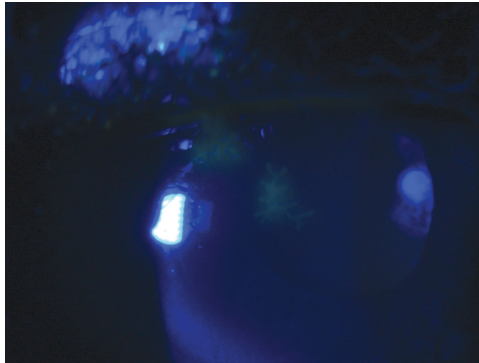


Figure 1.

A 46-year-old man presented to the emergency department with unilateral pain in his left eye that began one day earlier. He had redness and a foreign body sensation. There were no vision changes, discharge, trauma, or recent upper respiratory tract symptoms.

On examination, his pupils were reactive to light with normal ocular motor function. He had consensual photophobia. Slit lamp examination showed ciliary flush and cell flaring, but no conjunctival injection. The patient was further evaluated with fluorescein staining (*Figure 1*).

Question

Based on the patient's history, physical examination, and microscopy findings, which one of the following is the most likely diagnosis?

- A. Foreign body.
- B. Fungal keratitis.
- C. Herpes keratitis.
- D. Sarcoidosis.

See the following page for discussion.

Discussion

The answer is C: herpes keratitis. Herpes simplex virus is one of the leading causes of infectious keratitis resulting in blindness. Herpes keratitis is the most common ocular form of herpes infection and usually presents as an infection of the superficial epithelium with dendritic lesions in this layer.¹ Symptoms of herpes keratitis vary but may include pain, blurred vision, sensitivity to light, red eye, watery discharge, or foreign body sensation. Recurrent episodes are common.

The diagnosis is made based on history and slit lamp examination.¹ This patient's examination with fluorescein staining revealed a dendritic lesion (*Figure 2*). Laboratory testing is generally not indicated. Herpes keratitis is treated with antiviral therapy.²

Patients with a foreign body may have excruciating pain, tearing, and a scratchy sensation with blinking. Slit lamp examination may reveal a foreign body in the anterior or posterior chamber. However, if the object is not present, fluorescein staining may demonstrate a corneal epithelial injury or defect.¹

Patients with fungal keratitis may have a history of trauma with vegetative matter, or long-term steroid use.^{1,3} Common

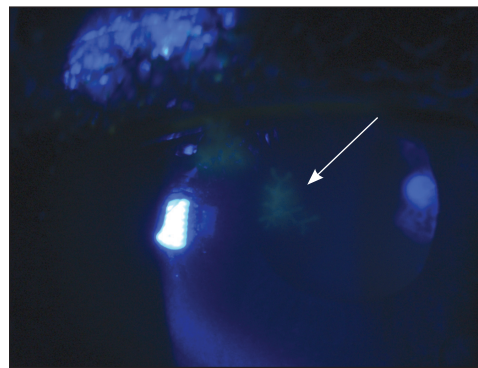


Figure 2. Slit lamp examination with fluorescein staining shows a dendritic lesion (*arrow*) in a patient with herpes keratitis.

symptoms include pain, red eye, foreign body sensation, and discharge. Typical slit light examination findings include a dry, gray, elevated infiltrate and satellite lesions. Diagnosis requires laboratory confirmation using a fungal culture.

Ocular sarcoidosis can manifest before the presentation of systemic sarcoidosis. Uveitis is a common ocular manifestation of sarcoidosis.⁴ Examination shows redness in the corneal area. Patients present with bilateral ocular pain, photophobia, and decreased vision, and granuloma formation can be seen in the conjunctiva and uvea.

The opinions and assertions contained herein are the private views of the authors and are not to be construed as official or as reflecting the views of the U.S. Navy Medical Department or the U.S. Navy at large.

Address correspondence to Mohenish Singh, LT, MC, USN, at Mohenish.Singh@med.navy.mil. Reprints are not available from the authors.

Author disclosure: No relevant financial affiliations to disclose.

REFERENCES

1. Kunimoto DY, Kanitkar KD, Makar M; Wills Eye Hospital. *The Wills Eye Manual. Office and Emergency Room Diagnosis and Treatment of Eye Disease*. 5th ed. Philadelphia, Pa.: Lippincott Williams & Wilkins; 2008.
2. Guess S, Stone DU, Chodosh J. Evidence-based treatment of herpes simplex virus keratitis: a systematic review. *Ocul Surf*. 2007;5(3):240-250.
3. Thomas PA. Fungal infections of the cornea. *Eye (London)*. 2003;17(8):852-862.
4. Heiligenhaus A, Wefelmeyer D, Wefelmeyer E, Rösel M, Schrenk M. The eye as a common site for the early clinical manifestation of sarcoidosis. *Ophthalmic Res*. 2011;46(1):9-12. ■

Summary Table		
Condition	Examination findings	Characteristics
Foreign body	Foreign body in anterior or posterior chamber; corneal epithelial injury/defect	Excruciating pain, tearing, scratchy sensation with blinking
Fungal keratitis	Dry, gray, elevated infiltrate, and satellite lesions	History of trauma with vegetative matter, or long-term steroid use; pain, red eye, foreign body sensation, or discharge
Herpes keratitis	Dendritic lesions in the epithelial layer	Pain, blurred vision, sensitivity to light, red eye, foreign body sensation, or watery discharge
Uveitis from sarcoidosis	Redness in corneal area, decreased visual acuity	Bilateral ocular pain and photophobia; granuloma formation in the conjunctiva and uvea