

Neglected Parasitic Infections: What Every Family Physician Needs to Know

DANA WOODHALL, MD; JEFFREY L. JONES, MD, MPH; PAUL T. CANTEY, MD, MPH; PATRICIA P. WILKINS, PhD; and SUSAN P. MONTGOMERY, DVM, MPH, *Centers for Disease Control and Prevention, Atlanta, Georgia*

Neglected parasitic infections, including Chagas disease, toxocariasis, cysticercosis, and toxoplasmosis, affect millions of persons in the United States. Relatively few resources have been devoted to surveillance, prevention, and treatment of these diseases. Chagas disease primarily affects Latin American immigrants and can cause heart failure and death if not treated. Immediate antiparasitic treatment is indicated for most patients with acute Chagas disease. Treatment is recommended for patients younger than 18 years who have chronic Chagas disease and is generally recommended for adults younger than 50 years who do not have advanced cardiomyopathy; treatment decisions for other patients should be made on an individual basis. Toxocariasis primarily affects children and can cause gastrointestinal, respiratory, and ophthalmologic disease. Treatment options include albendazole and mebendazole. Patients with ocular infection require referral to an ophthalmologist. Neurocysticercosis, a form of cysticercosis, is the most common infectious cause of seizures in some parts of the United States. Initial treatment should focus on symptom control. Humans generally acquire toxoplasmosis by eating undercooked contaminated meat or ingesting things that have been contaminated with cat feces. Congenital infection can result in miscarriage or adverse fetal effects. Treatment is recommended for immunosuppressed persons, pregnant women, and immunocompetent persons with severe symptoms. (*Am Fam Physician*. 2014;89(10):803-811. Copyright © 2014 American Academy of Family Physicians.)

CME This clinical content conforms to AAFP criteria for continuing medical education (CME). See CME Quiz Questions on page 792.

Author disclosure: No relevant financial affiliations.

Neglected parasitic infections, including Chagas disease, toxocariasis, cysticercosis, and toxoplasmosis, can cause severe illness, but limited resources have been devoted to better understanding their impact and burden. Physicians may not be familiar with these infections because their clinical presentation, diagnosis, and treatment are typically not emphasized during medical training. However, it is crucial for family physicians to understand the basic principles of diagnosis and treatment of these diseases. A summary of the key points about epidemiology, clinical manifestations, diagnostic evaluation, and treatment for each disease is presented in *Table 1*.

Chagas Disease

Chagas disease, also known as American trypanosomiasis, is caused by the parasite *Trypanosoma cruzi*. Transmission to humans occurs mainly through contact with insects. Infection occurs when an infected triatomine defecates after a blood meal and the feces, which contains the parasite, is rubbed into the bite wound or mucous membranes

(*Figure 1*).¹ Transmission can also occur congenitally or via blood transfusion, organ transplantation, contaminated food, or laboratory exposure. Chagas disease is endemic throughout Mexico and Central and South America, where an estimated 8 to 11 million persons are infected.² More than 300,000 persons in the United States are thought to be infected,² most of whom acquired the disease in Latin America. However, infected triatomines have been found in the United States, and domestic vector-borne transmission has occurred.³

There are two phases of the disease: acute, which lasts for weeks or months after the initial infection, and chronic. Infection is lifelong in the absence of treatment. Clinical manifestations are often mild or absent in the acute phase; swelling around the bite site may be present. If the inoculation site is the conjunctiva, unilateral palpebral edema may occur. Most patients with chronic Chagas disease remain asymptomatic, but 20% to 30% of persons with the infection develop clinical manifestations that can be life-threatening.⁴ Cardiac disease, including conduction abnormalities, apical aneurysm,

Table 1. Key Points About Chagas Disease, Toxocariasis, Cysticercosis, and Toxoplasmosis

Disease	Epidemiology and transmission	Clinical manifestations
Chagas disease (American trypanosomiasis)	<p>More than 300,000 persons in the United States are infected; more common in immigrants from Mexico and Central or South America, and in those who have visited endemic areas</p> <p>Transmission is most often vector-borne (triatomines), congenital, or via blood transfusion or organ transplantation</p> <p>Blood donations are screened for the disease; donors whose blood tests positive cannot donate again</p>	<p>Acute infection: Typically four to eight weeks after infection; usually asymptomatic; nonspecific febrile illness, swelling around the bite site</p> <p>Chronic infection: 20% to 30% of persons develop symptoms, including cardiac and gastrointestinal manifestations; increased risk of stroke</p> <p>Congenital infection: Usually asymptomatic; anemia, hepatosplenomegaly, low Apgar scores, low birth weight, thrombocytopenia; rarely, meningoencephalitis, myocarditis</p>
Toxocariasis	<p>More common in children, pet owners, and persons with geophagia; estimated serologic prevalence in the United States is 13.9%</p> <p>Transmission occurs by ingesting <i>Toxocara</i> eggs in soil contaminated with feces from an infected dog or cat, or by eating undercooked meat from an infected animal</p>	<p>Usually asymptomatic</p> <p>Visceral infection: Abdominal pain, anemia, anorexia, coughing, eosinophilia, fatigue, fever, hepatomegaly, hypergammaglobulinemia, meningoencephalitis, wheezing</p> <p>Ocular infection: Peripheral granuloma with traction bands, posterior pole granuloma, strabismus, subretinal granulomatous mass, unilateral vision loss</p>
Cysticercosis	<p>More common in immigrants from Central and South America, but can occur in persons who have not traveled outside the United States</p> <p>Transmission occurs by ingesting eggs excreted in the feces of a tapeworm carrier; transmission does not occur by eating undercooked infected pork</p>	<p>Neurocysticercosis: May be asymptomatic; seizures are the most common manifestation; chronic meningitis, cranial nerve abnormalities, headache, and intracranial hypertension or hydrocephalus may also occur</p> <p>Muscular cysticerci are usually asymptomatic; ocular cysticerci may cause blurry vision</p>
Toxoplasmosis	<p>More than 60 million persons in the United States are infected; symptomatic infection is more common in immunocompromised persons and in children with congenital infection</p> <p>Transmission is most often foodborne, zoonotic (from cat feces), or congenital</p>	<p>Most immunocompetent persons are asymptomatic; those who are immunosuppressed may develop encephalitis with confusion, fever, headache, poor coordination, or seizures; women infected during pregnancy may have a miscarriage or a child born with signs of toxoplasmosis; ocular symptoms may include eye pain, blurred vision, or photophobia</p>

or heart failure, may occur. Gastrointestinal manifestations include megaesophagus or megacolon. Stroke risk is increased in patients infected with *T. cruzi*. Congenitally infected infants are often asymptomatic; some may have low birth weight or low Apgar scores, or may develop anemia, thrombocytopenia, or hepatosplenomegaly. Rarely, myocarditis or meningoencephalitis may occur in infants with congenital infection.

Acute or congenital Chagas disease is diagnosed by detection of parasites via direct microscopy of anticoagulated cord

blood or peripheral blood; polymerase chain reaction testing may also be used to detect acute infection. After the acute phase, few or no parasites are present; serologic testing for antibodies to *T. cruzi* is required to diagnose chronic Chagas disease. Because no single serologic test has sufficient sensitivity and specificity to confirm the diagnosis, positive results on at least two different tests are required for diagnosis. Since 2007, U.S. blood donors have been screened for *T. cruzi* infection. Those with positive results can no longer donate blood, regardless of confirmatory test results, and are advised to consult

<i>Diagnosis</i>	<i>Treatment</i>
<p>Acute and congenital infections: Direct microscopy of peripheral or umbilical cord blood to detect parasites; polymerase chain reaction testing also available</p> <p>Chronic infection: No or few parasites in the blood; multiple serologic tests with varying sensitivity and specificity are available; at least two positive results on serologic tests required for diagnosis</p>	<p>Infection is lifelong without treatment; persons with acute or congenital infection should be treated, as should immunocompromised persons with reactivated infection; pregnant women and persons with severe renal or hepatic insufficiency should not be treated; for chronic disease, treatment is recommended in persons younger than 18 years and in those younger than 50 years who do not have severe cardiomyopathy; all others should be treated on a case-by-case basis</p> <p>Treatment options include nifurtimox or benznidazole (available through the Centers for Disease Control and Prevention)</p>
<p><i>Toxocara</i> antibody test (does not differentiate between acute and previous infection); stool examination is not useful because eggs are not excreted by humans</p>	<p>Treatment options include albendazole (Albenza) and mebendazole; corticosteroids may be used to suppress inflammation in patients with ocular infection; patients with ocular infection should be referred to an ophthalmologist for possible surgery</p>
<p>Neurocysticercosis: Combination of serologic testing and computed tomography or magnetic resonance imaging; number, location, and viability of cysticerci should be determined</p>	<p>Neurocysticercosis: Symptom control is priority; decision to treat with anthelmintic drugs should be individualized; coadministration of corticosteroids may decrease inflammatory response</p> <p>Persons with cysticercosis and close contacts should be screened for tapeworm infection</p>
<p><i>Toxoplasma</i> antibody test (immunoglobulin M for recent infection; immunoglobulin G for chronic infection); serologic tests may be unreliable in immunosuppressed patients; microscopy to detect parasite in blood, cerebrospinal fluid, or tissue; polymerase chain reaction testing also available</p>	<p>Spiramycin should be used before amniocentesis to assess fetal infection in pregnant women who acquire infection in the first or early second trimester</p> <p>Pyrimethamine (Daraprim), sulfadiazine, and leucovorin should be used in infants with congenital infection, in pregnant women who acquire infection in the late second or third trimester or who acquire the infection earlier and transmit it to the fetus, in immunosuppressed patients, and in immunocompetent patients with severe symptoms</p>

with their physician for further workup and confirmation of infection.

Patients with newly diagnosed Chagas disease should have a physical examination with electrocardiography. Children whose mothers have Chagas disease should also be tested. Immediate antiparasitic treatment is indicated for patients with acute disease, including those with congenital infection and immunocompromised patients with reactivated disease.⁵ Pregnant women and patients with severe hepatic or renal insufficiency should not be treated because of adverse drug effects. Treatment is recommended

for patients younger than 18 years who have chronic Chagas disease and is generally recommended for adults younger than 50 years who do not have advanced cardiomyopathy; treatment decisions for other patients should be made on an individual basis.^{2,5} Benznidazole and nifurtimox are used to treat Chagas disease. Neither drug is approved by the U.S. Food and Drug Administration, but they are available through the Centers for Disease Control and Prevention under investigational protocols.⁵ A treatment course ranges from 60 to 90 days, and adverse effects include weight loss, anorexia, and polyneuropathy.

Toxocariasis

Toxocariasis is caused by the roundworms *Toxocara canis* and *Toxocara cati* and occurs anywhere dogs or cats are present. After an infected dog or cat passes *Toxocara* eggs in its feces, it takes about two to four weeks for larvae to develop and for the eggs to become infectious; humans become infected by ingesting *Toxocara* eggs or by eating undercooked meat from an animal infected with *Toxocara* larvae (Figure 2).⁶ The seroprevalence of *Toxocara* infection in the United States is estimated to be 13.9%; however, the proportion of persons who have clinical toxocariasis is unknown.⁷ Studies have shown soil samples to have contamination rates as high as 40%, especially in areas frequented by dogs and cats (e.g., sandboxes, playgrounds).⁸ Children are at high risk of infection because they often visit these areas and ingest dirt as a result of their play habits and hygiene. Geophagia (i.e., the deliberate consumption of soil) and owning a dog or cat are other factors that increase the risk of

infection. The development of clinical disease depends on the parasite load, the host's immune response, and the migration path of the larvae; most patients infected with *Toxocara* remain asymptomatic.

Three clinical manifestations of toxocariasis have been described: visceral, ocular, and covert toxocariasis (also called common toxocariasis). Visceral toxocariasis is typically diagnosed in young children (mean age of two to four years) and is characterized by a marked inflammatory response to larvae migrating to the liver or other tissues. Signs and symptoms are often nonspecific and may include fever, wheezing, coughing, abdominal pain, hepatomegaly, meningoencephalitis, anorexia, and fatigue. Laboratory findings often include eosinophilia; anemia or hypergammaglobulinemia may also be present. Ocular toxocariasis occurs when a *Toxocara* larva migrates to the eye, resulting in inflammation and scarring that can lead to vision loss. It typically occurs in slightly older children (mean age of five to eight years).

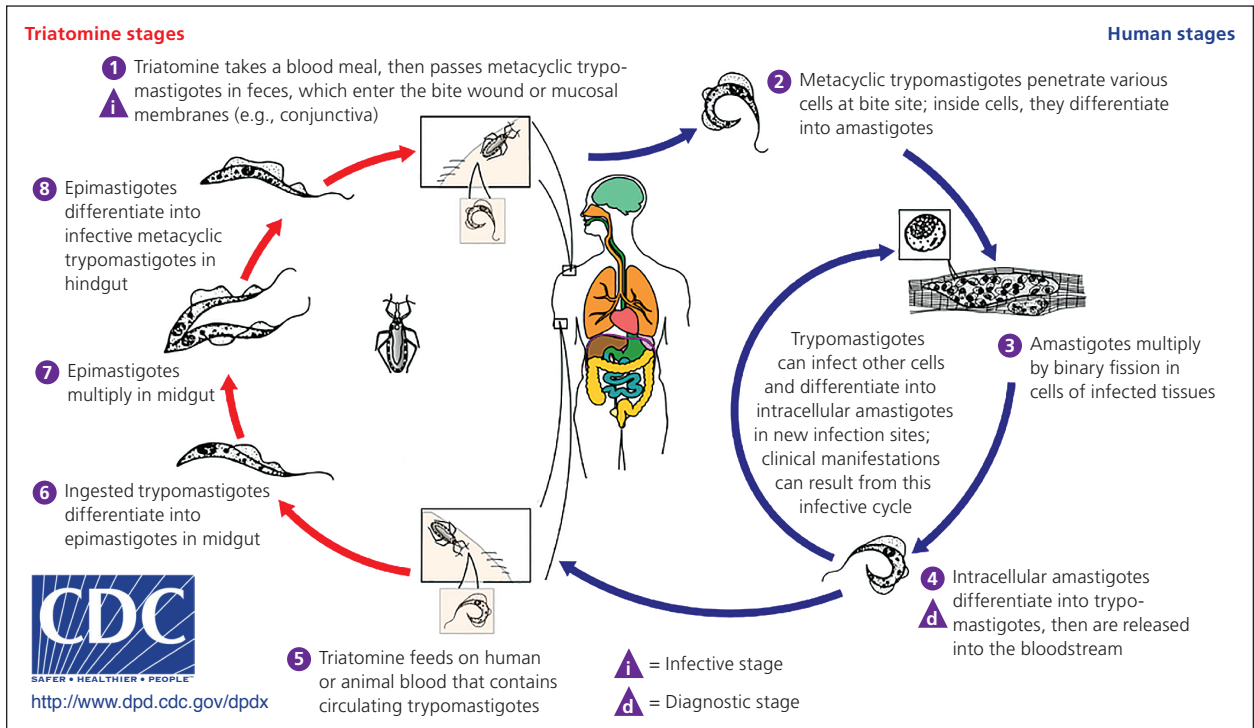


Figure 1. Transmission cycle of Chagas disease.

Adapted from Centers for Disease Control and Prevention. American trypanosomiasis (*Trypanosoma cruzi*). <http://www.cdc.gov/dpdx/trypanosomiasis/American/index.html>. Accessed February 4, 2014.

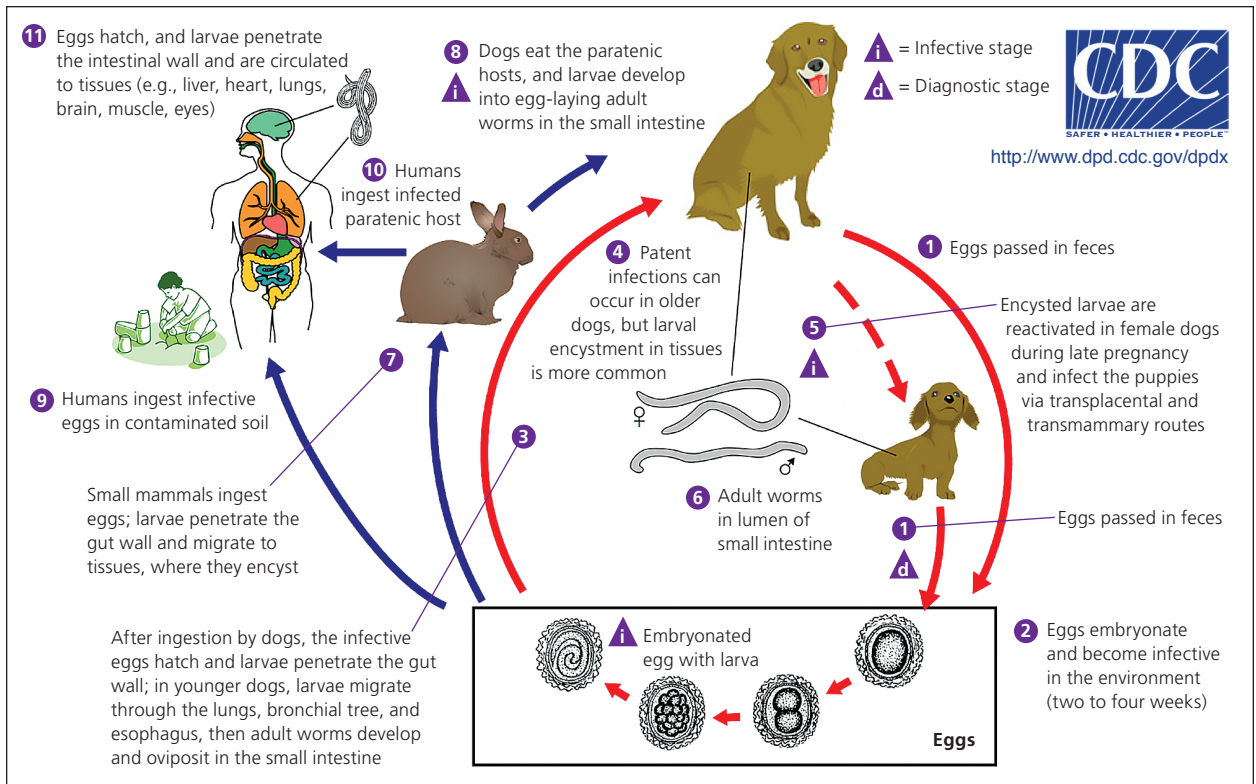


Figure 2. Transmission cycle of toxocariasis.

Adapted from Centers for Disease Control and Prevention. *Toxocariasis* (*Toxocara canis*, *Toxocara cati*). <http://www.cdc.gov/dpdx/toxocariasis/index.html>. Accessed February 4, 2014.

Common ophthalmologic findings include subretinal granulomatous mass, posterior pole granuloma, unilateral vision loss, strabismus, and peripheral granuloma with traction bands; usually, only one eye is affected. Patients with ocular toxocariasis often have a normal eosinophil count. In covert toxocariasis, symptoms are mild and nonspecific.

Serologic testing for *Toxocara* antibodies is available, although a positive result does not differentiate between acute and previous infection. Stool examination is not helpful because *Toxocara* larvae do not mature into adult worms that excrete eggs in humans.

Treatment options for toxocariasis include albendazole (Albenza) and mebendazole. A five-day course is generally sufficient, although there is a lack of data regarding optimal treatment duration.⁹ Corticosteroids should be prescribed if evidence of inflammation is present; this is especially important to prevent scarring in patients with ocular toxocariasis, which may lead to permanent vision loss. Patients with ocular infection require close follow-up with an ophthalmologist, and surgery may be warranted. Strategies to prevent *Toxocara* infection include prompt

disposal of pet feces, routine deworming of pets, and hygiene techniques such as hand washing and teaching children not to eat dirt.

Cysticercosis

Cysticercosis, a tissue infection with encysted *Taenia solium* larvae, is acquired by ingesting eggs excreted in the feces of a human carrier of a pork tapeworm (Figure 3).¹⁰ Taeniasis, an intestinal infection with the adult *T. solium* tapeworm, is acquired when a human ingests undercooked pork infected with cysticerci, or larval cysts. Persons with taeniasis shed tapeworm eggs in the feces, which can contaminate the environment in settings where personal hygiene practices are poor. Once the infectious eggs are ingested, they migrate into tissues and develop into cysticerci. In the United States, the highest prevalence of cysticercosis occurs in immigrants from Central and South America who acquired the infection in their home country; however, up to 15% of patients in a study of cysticercosis-associated deaths were U.S. natives.¹¹ Having a household contact with taeniasis increases the risk of cysticercosis.

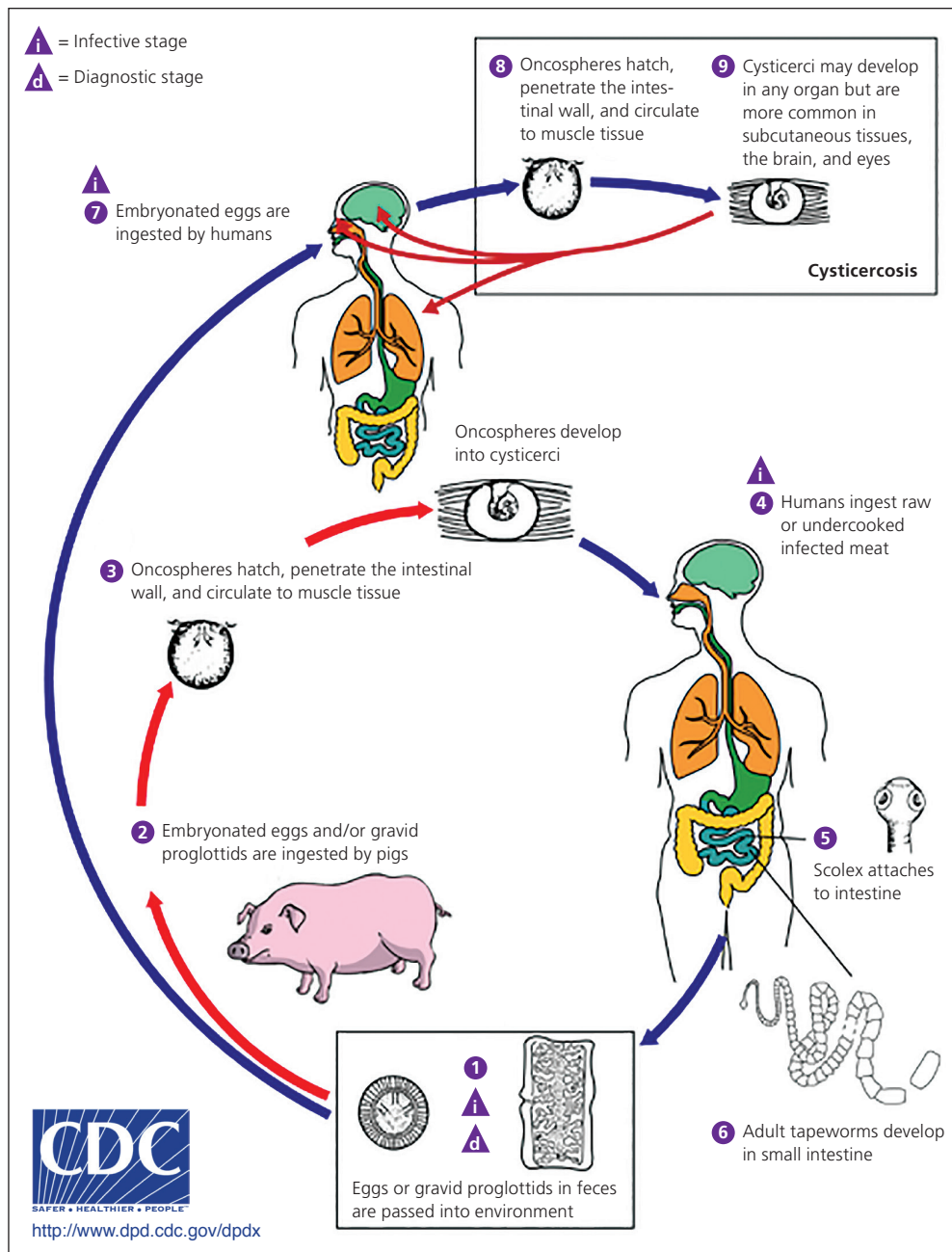


Figure 3. Transmission cycle of cysticercosis.

Adapted from Centers for Disease Control and Prevention. *Cysticercosis (Taenia solium)*. <http://www.cdc.gov/dpdx/cysticercosis/index.html>. Accessed February 4, 2014.

Cysticerci can develop in the muscles, eyes, brain, and spinal cord; symptom onset varies from months to years from time of initial infection. Symptoms are most often caused by the inflammatory response to dying parasites, although they can be caused by mass effect. Subcutaneous and muscular cysticerci are generally asymptomatic, although lumps may develop under the skin. Neurocysticercosis occurs when cysticerci invade the central nervous system. The most

common clinical manifestations are seizures, which occur in 50% to 80% of symptomatic patients with parenchymal cysts, and intracranial hypertension or hydrocephalus, which occurs in 20% to 30% of symptomatic patients.¹² Other manifestations include headache, chronic meningitis, and cranial nerve abnormalities. Parenchymal disease with few cysts has a better long-term prognosis than extraparenchymal disease or infection with large numbers of cysts.

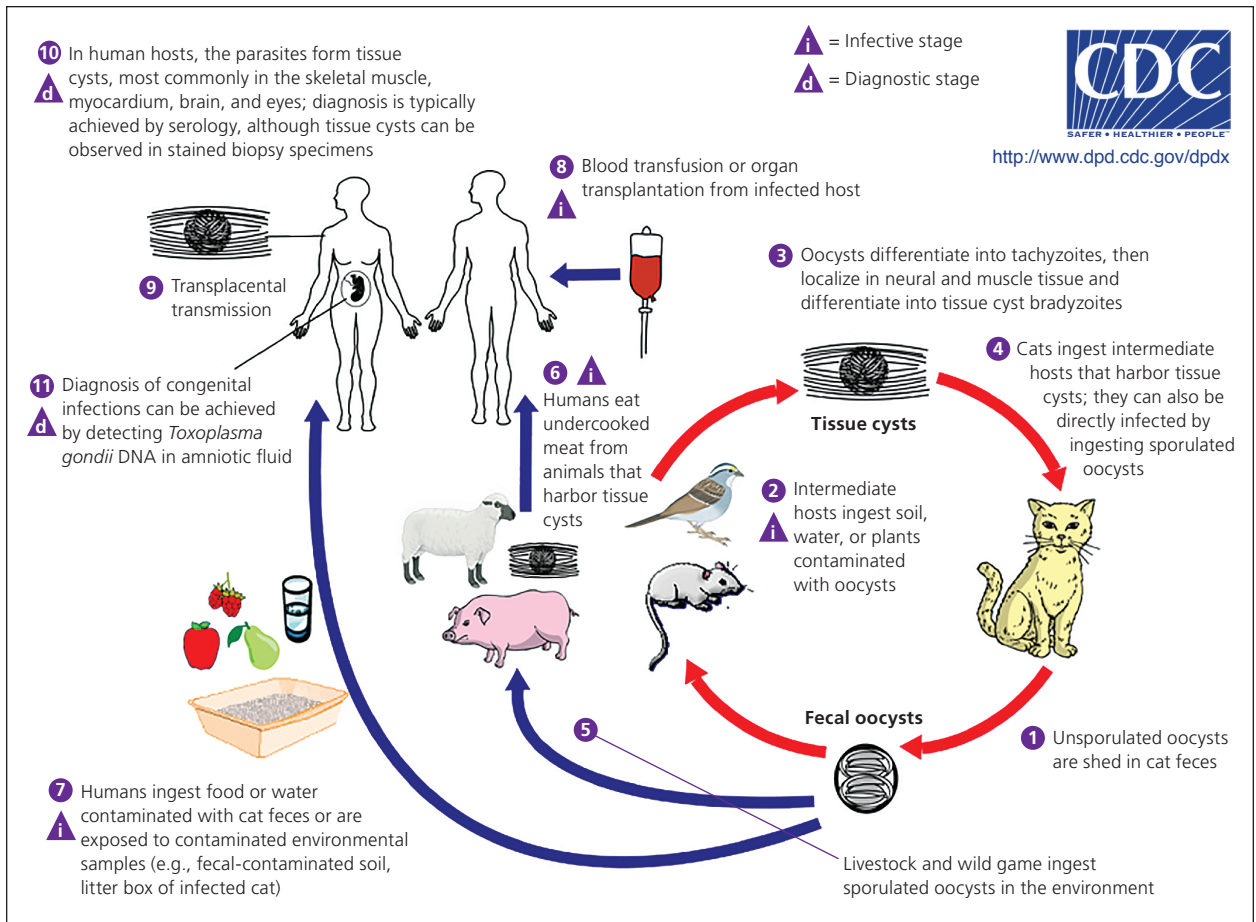


Figure 4. Transmission cycle of toxoplasmosis.

Adapted from Centers for Disease Control and Prevention. *Toxoplasmosis (Toxoplasma gondii)*. <http://www.cdc.gov/dpdx/toxoplasmosis/index.html>. Accessed February 4, 2014.

A combination of serologic testing and neuroimaging with computed tomography or magnetic resonance imaging is typically required for diagnosis. An enzyme-linked immunoelectrotransfer blot is the preferred serologic test because of its sensitivity and specificity. Initial treatment of neurocysticercosis should focus on symptom control (e.g., antiepileptic drugs for seizures, neurosurgery for hydrocephalus), not on immediate initiation of anthelmintic therapy. Once symptoms are controlled, anthelmintic therapy should be individualized and take into account the patient's symptoms and the number, viability, and location of cysticerci.¹³ Treatment, usually with albendazole, can cause a severe inflammatory reaction by killing viable cysts; corticosteroids should be used to suppress this response.¹⁴

Persons diagnosed with cysticercosis, as well as their close contacts, should be screened for taeniasis and treated, if necessary. Strategies to prevent cysticercosis include wash-

ing hands, raw vegetables, and fruits before eating. Persons traveling to endemic areas should drink only boiled or bottled water and eat only fruits and vegetables that have been cooked or that they have peeled themselves.

Toxoplasmosis

Toxoplasmosis is caused by the parasite *Toxoplasma gondii*. Humans often acquire *Toxoplasma* infection by eating undercooked contaminated meat; by eating food contaminated by utensils or cutting boards that have been in contact with raw contaminated meat; by ingesting soil contaminated with cat feces on raw fruits or vegetables; or by drinking contaminated water (Figure 4).¹⁵ Transmission via blood transfusion or organ transplantation can also occur. Cats are often infected with *T. gondii* and can shed the parasite in their feces for several weeks when they are newly infected. Cleaning a cat's litter box is a high-risk activity. Congenital transmission usually occurs when a woman

is newly infected with *T. gondii* during or just before pregnancy.

More than 60 million persons in the United States are infected with *Toxoplasma*, although most immunocompetent persons remain asymptomatic.¹⁶ Some experience mild flu-like symptoms, including myalgias or lymphadenopathy, that typically resolve over several weeks. Congenital infections can result in miscarriage or a child born with signs of toxoplasmosis (e.g., jaundice, macrocephaly, microcephaly, seizures). However, infected infants are often asymptomatic at birth.

Immunosuppressed patients who are infected with *T. gondii* may have severe symptoms of encephalitis, including fever, headache, seizures, confusion, or poor coordination, usually from reactivation of a previous infection. Ocular disease, usually retinochoroiditis, may also develop; patients may present with blurred vision, eye pain, and photophobia. Ocular disease develops in 20% to 80% of persons with congenital infection, but signs are sometimes not present until adulthood.¹⁷ In the United States, less than 2% of persons who are infected with *T. gondii* after birth develop ocular disease.¹⁷

Serologic tests that detect *Toxoplasma* antibodies are available. Immunoglobulin M (IgM) is useful in determining whether infection is recent; IgG reflects chronic infection but may also be present in acute infections. Because false-positive results may occur with IgM testing, it should generally be ordered with an IgG test. The *Toxoplasma* avidity test can also help determine the timing of infection. Other diagnostic tests (e.g., polymerase chain reaction testing; direct observation of the parasite in blood, tissue, or cerebrospinal fluid) may be useful, especially in immunosuppressed patients in whom the diagnosis may be difficult to confirm. If congenital transmission is a concern, polymerase chain reaction testing can be performed on amniotic fluid as early as 18 weeks' gestation.

Treatment of immunocompetent adults is rarely warranted; if visceral disease is

present or symptoms are severe, pyrimethamine (Daraprim), sulfadiazine, and leucovorin may be given for two to four weeks. Immunosuppressed persons with toxoplasmosis require continuous treatment until their immunologic state has improved.¹⁸ Women who are infected during the first or early second trimester of pregnancy should be treated with spiramycin.¹⁹ When fetal infection is confirmed by amniocentesis, or for infection occurring in the late second or third trimester, pyrimethamine, sulfadiazine, and leucovorin are usually given; infants with congenitally acquired infection should also receive pyrimethamine, sulfadiazine, and leucovorin.¹⁸ Pregnant women and immunosuppressed persons should not change cat litter boxes or adopt stray cats. To prevent toxoplasmosis, meat should be cooked thoroughly and items that have been in contact with raw meat should be washed.

Additional Resources

Further information about Chagas disease, toxocariasis, cysticercosis, and toxoplasmosis is available through the Centers for Disease Control and Prevention's website (<http://www.cdc.gov/parasites/npi.html>). Resources include fact sheets for patients and physicians, continuing medical education courses, and audio podcasts for each disease. Consultation with experts and information about diagnostic testing and investigational drugs are available through the Parasitic Diseases Branch Public Inquiries desk (telephone: 404-718-4745; e-mail: parasites@cdc.gov).

Data Sources: A PubMed search was completed in Clinical Queries using the key terms epidemiology, diagnosis, treatment, and United States for each of the following diseases: Chagas disease, cysticercosis, toxocariasis, and toxoplasmosis. The search included meta-analyses, randomized controlled trials, clinical trials, and reviews. Search dates: October 2012 through February 2014.

The Authors

DANA WOODHALL, MD, is a medical officer in the Parasitic Diseases Branch of the Centers for Disease Control and Prevention in Atlanta, Ga.

JEFFREY L. JONES, MD, MPH, is a medical officer in the Parasitic Diseases Branch of the Centers for Disease Control and Prevention.

Pregnant women and immunosuppressed persons should not change cat litter boxes or adopt stray cats.

PAUL T. CANTEY, MD, MPH, is a medical officer in the Parasitic Diseases Branch of the Centers for Disease Control and Prevention.

PATRICIA P. WILKINS, PhD, is an associate director for laboratory science in the Parasitic Diseases Branch of the Centers for Disease Control and Prevention.

SUSAN P. MONTGOMERY, DVM, MPH, is a veterinary medical officer in the Parasitic Diseases Branch of the Centers for Disease Control and Prevention.

Address correspondence to Dana Woodhall, MD, Centers for Disease Control and Prevention, 1600 Clifton Rd., Mail Stop D-03, Atlanta, GA 30333 (e-mail: dqw6@cdc.gov). Reprints are not available from the authors.

REFERENCES

- Centers for Disease Control and Prevention. American trypanosomiasis (*Trypanosoma cruzi*). <http://www.cdc.gov/dpdx/trypanosomiasisAmerican/index.html>. Accessed February 4, 2014.
- Bern C, Montgomery SP. An estimate of the burden of Chagas disease in the United States. *Clin Infect Dis*. 2009;49(5):e52-e54.
- Bern C, Kjos S, Yabsley MJ, Montgomery SP. *Trypanosoma cruzi* and Chagas' disease in the United States. *Clin Microbiol Rev*. 2011;24(4):655-681.
- Rassi A Jr, Rassi A, Marin-Neto JA. Chagas disease. *Lancet*. 2010;375(9723):1388-1402.
- Bern C, Montgomery SP, Herwaldt BL, et al. Evaluation and treatment of Chagas disease in the United States: a systematic review. *JAMA*. 2007;298(18):2171-2181.
- Centers for Disease Control and Prevention. Toxocariasis (*Toxocara canis*, *Toxocara cati*). <http://www.cdc.gov/dpdx/toxocariasis/index.html>. Accessed February 4, 2014.
- Won KY, Kruszon-Moran D, Schantz PM, Jones JL. National seroprevalence and risk factors for zoonotic *Toxocara* spp. infection. *Am J Trop Med Hyg*. 2008;79(4):552-557.
- Dada BJ, Lindquist WD. Prevalence of *Toxocara* spp. eggs in some public grounds and highway rest areas in Kansas. *J Helminthol*. 1979;53(2):145-146.
- Toxocariasis (visceral larva migrans, ocular larva migrans). In: Pickering LK, Baker CJ, Kimberlin DW, Long SS, eds. *Red Book: 2009 Report of the Committee on Infectious Diseases*. 28th ed. Elk Grove Village, Ill.: American Academy of Pediatrics; 2009:666-667.
- Centers for Disease Control and Prevention. Cysticercosis (*Taenia solium*). <http://www.cdc.gov/dpdx/cysticercosis/index.html>. Accessed February 4, 2014.
- Sorvillo FJ, DeGiorgio C, Waterman SH. Deaths from cysticercosis, United States. *Emerg Infect Dis*. 2007;13(2):230-235.
- García HH, Gonzalez AE, Evans CA, Gilman RH; Cysticercosis Working Group in Peru. *Taenia solium* cysticercosis. *Lancet*. 2003;362(9383):547-556.
- Del Brutto OH, Santibañez R, Noboa CA, Aguirre R, Díaz E, Alarcón TA. Epilepsy due to neurocysticercosis: analysis of 203 patients. *Neurology*. 1992;42(2):389-392.
- García HH, Del Brutto OH; Cysticercosis Working Group in Peru. Neurocysticercosis: updated concepts about an old disease. *Lancet Neurol*. 2005;4(10):653-661.
- Centers for Disease Control and Prevention. Toxoplasmosis (*Toxoplasma gondii*). <http://www.cdc.gov/dpdx/toxoplasmosis/index.html>. Accessed February 4, 2014.
- Jones JL, Kruszon-Moran D, Wilson M. *Toxoplasma gondii* infection in the United States, 1999-2000. *Emerg Infect Dis*. 2003;9(11):1371-1374.
- Holland GN. Ocular toxoplasmosis: a global reassessment. Part I: epidemiology and course of disease. *Am J Ophthalmol*. 2003;136(6):973-988.
- Panel on Opportunistic Infections in HIV-Infected Adults and Adolescents. Guidelines for the prevention and treatment of opportunistic infections in HIV-infected adults and adolescents. http://aidsinfo.nih.gov/contentfiles/lvguidelines/adult_oi.pdf. Accessed April 2, 2014.
- Montoya JG, Remington JS. Management of *Toxoplasma gondii* infection during pregnancy. *Clin Infect Dis*. 2008;47(4):554-566.