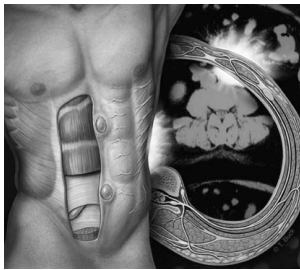

# The Abdominal Wall: An Overlooked Source of Pain

SAUD SULEIMAN, M.D., and DAVID E. JOHNSTON, M.D.  
University of New Mexico School of Medicine, Albuquerque, New Mexico

**When abdominal pain is chronic and unremitting, with minimal or no relationship to eating or bowel function but often a relationship to posture (i.e., lying, sitting, standing), the abdominal wall should be suspected as the source of pain. Frequently, a localized, tender trigger point can be identified, although the pain may radiate over a diffuse area of the abdomen. If tenderness is unchanged or increased when abdominal muscles are tensed (positive Carnett's sign), the abdominal wall is the likely origin of pain. Most commonly, abdominal wall pain is related to cutaneous nerve root irritation or myofascial irritation. The pain can also result from structural conditions, such as localized endometriosis or rectus sheath hematoma, or from incisional or other abdominal wall hernias. If hernia or structural disease is excluded, injection of a local anesthetic with or without a corticosteroid into the pain trigger point can be diagnostic and therapeutic. (Am Fam Physician 2001;64:431-8.)**



The abdominal wall as a source of pain has received little attention, and only a few reviews on the topic have been published in the past decade.<sup>1,2</sup> However, physicians who consider abdominal wall pain in their patients often find it. In fact, overlooking the abdominal wall as a source of pain can result in a prolonged, expensive, frustrating and dangerous evaluation.

## Evaluation

In patients with acute or chronic abdominal pain, a number of clinical findings point to disease inside the abdomen (*Table 1*). When such findings are absent, consideration should be given to the abdominal wall as the source of pain.

In chronic abdominal pain, the abdominal wall often can be implicated based on the findings of the history and physical examination. This is especially

true if the pain is not progressive and if no evidence of visceral disease is present.

Certain features may point to a pain source in the abdominal wall (*Table 2*). Unlike pain that originates in the digestive tract, pain from the abdominal wall is not made better or worse with food and is not altered by bowel movements. Furthermore, abdominal wall pain is often chronic, nagging and nonprogressive. An

TABLE 1  
**Some Features  
of Intra-abdominal Pain**

Nausea, vomiting, weight loss
Diarrhea, constipation or change in bowel habits
Pain not made better or worse by eating or bowel movements
Jaundice or other liver function test abnormalities
Bleeding or anemia
Fever
Laboratory evidence of inflammation*

\*—Elevated white blood cell count, sedimentation rate or C-reactive protein level.

*Pain that is the same or increased when the abdominal wall is tensed generally indicates an origin in the abdominal wall.*

TABLE 2

**Some Features of Abdominal Wall Pain**


---

Pain often constant or fluctuating; less often, episodic
Pain intensity possibly related to posture (e.g., lying, sitting, standing)
Pain not related to meals or bowel function
No findings of an intra-abdominal process (see Table 1)
Abdominal tenderness unchanged or increased when abdominal wall is tensed (positive Carnett's sign)
Discrete, tender pain trigger point no more than a few centimeters in diameter
Trigger points often found along lateral margins of the rectus abdominis muscles or at attachments of muscle or fascia
With stimulation of trigger point, referral of pain or spreading of pain over a large area

---

algorithm for the diagnosis and management of abdominal wall pain is provided in *Figure 1*.<sup>2</sup>

Tenderness originating from inside the abdominal cavity usually decreases when a supine patient tenses the abdominal wall by lifting head and shoulders off the examining table. In contrast, pain originating from the abdominal wall is unchanged or increased by this maneuver (positive Carnett's sign).<sup>3-5</sup>

A tender trigger point in the abdominal wall is frequently no more than 1 or 2 cm in diameter. However, it is not unusual for the pain to spread over a wide area or to be referred. For instance, pressing on a tender

trigger point in the right upper quadrant (nerve root T7) can refer pain to the angle of the scapula. Patients are often so preoccupied with the large area of pain spread that they do not realize the area of tenderness is extremely localized and superficial.

Several studies have demonstrated the value of the physical examination in the diagnosis of abdominal wall pain. Investigators in one study<sup>3</sup> found that of 120 emergency department admissions for acute abdominal pain, 23 of 24 patients with a positive Carnett's sign had a normal laparotomy. In another study<sup>4</sup> of 72 patients with obscure, chronic abdominal pain and a positive Carnett's sign, two patients were found to have pain related to spinal metastases from recurrence of known gynecologic malignancies; otherwise, when combined with other information from the history and physical examination, a positive Carnett's sign was found to be a reliable predictor of abdominal wall pain.

Investigators in yet another study<sup>5</sup> prospectively evaluated patients with chronic abdominal pain who met minimal criteria for abdominal wall pain. Criteria included a positive Carnett's sign or very superficial tenderness combined with pain that was constant or highly localized to an area no larger than a fingertip. Four patients proved to have visceral disease (esophagitis, bile duct stricture, diverticular disease and visceral neuropathy); these patients did not respond to the injection of a local anesthetic. Of the 79 patients in the study, 72 (91 percent) experienced at least 50 percent pain relief with one injection of local anesthetic, and at least 56 patients (78 percent) had permanent relief with one or two injections. Thus, when combined with other clinical criteria, a positive Carnett's sign is valuable as a sign of abdominal wall pain.

**Identifiable Causes****HERNIAS**

In addition to the familiar inguinal, femoral and umbilical hernias, a number of unusual hernias can occur (*Figure 2*). Among these are

**The Authors**

SAUD SULEIMAN, M.D., currently has a private practice in gastroenterology in Lewisville, Tex. Dr. Suleiman graduated from Damascus University School of Medicine, Syria. He completed a residency in internal medicine at Mercy Hospital Medical Center, Chicago, and a fellowship in gastroenterology at the University of New Mexico School of Medicine, Albuquerque.

DAVID E. JOHNSTON, M.D., currently is a gastroenterologist at The Everett (Wash.) Clinic. Previously, he was on the faculty of medicine at Tufts University School of Medicine, Boston, and the University of New Mexico School of Medicine. After graduating from the University of Pittsburgh School of Medicine, Dr. Johnston completed a residency in internal medicine at Brigham and Women's Hospital, Boston, and a fellowship in gastroenterology at New England Medical Center, also in Boston.

Address correspondence to David E. Johnston, M.D., Gastroenterology, The Everett Clinic, 3901 Hoyt Ave., Everett, WA 98201-4988 (e-mail: djohnston@everettclinic.com). Reprints are not available from the authors.

---

*The rightsholder did not grant rights to reproduce this item in electronic media. For the missing item, see the original print version of this publication.*

---

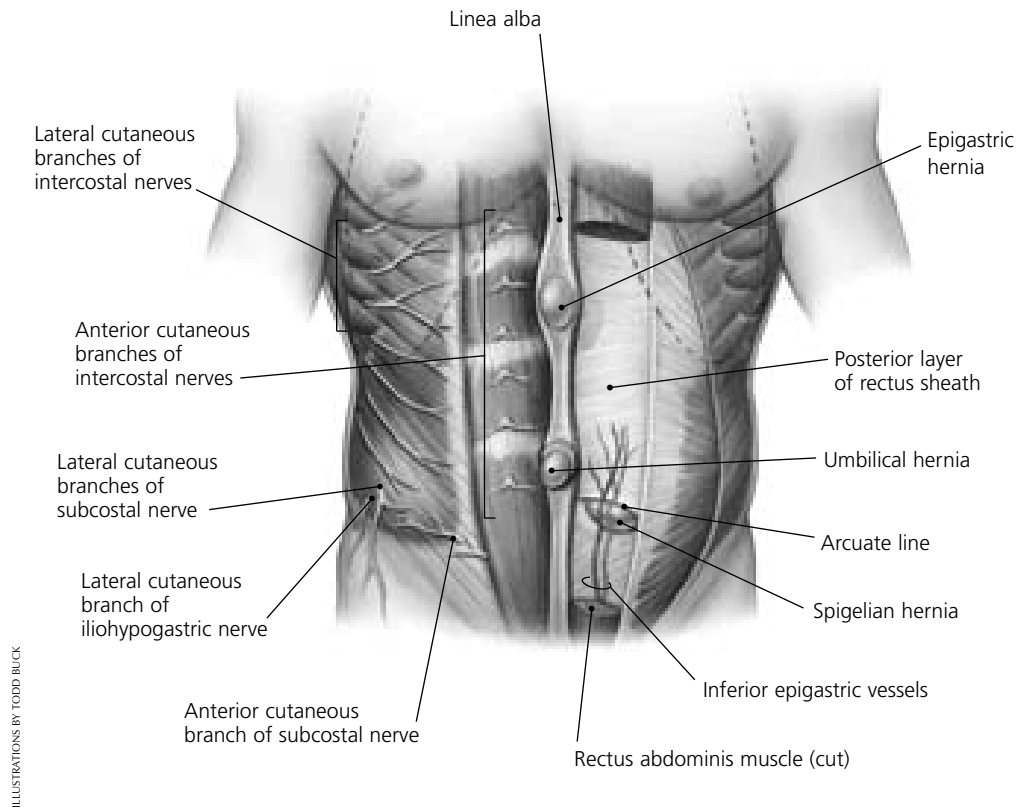
FIGURE 1. An algorithm for the diagnosis and management of abdominal wall pain.

the epigastric hernia in the upper midline and the more subtle spigelian hernia of the posterior lateral abdominal wall fascia, at the edge of the rectus sheath, which occurs in the mid-abdomen. Herniation of bowel loops often causes visceral pain with vomiting and bowel obstruction. However, when only omentum

becomes incarcerated in a hernia, severe pain can occur without bowel obstruction.

#### **Illustrative Case**

A 55-year-old woman presented with multiple episodes of right upper quadrant abdominal pain over the course of one year. The



**FIGURE 2.** Locations where pain in the abdominal wall might originate. Epigastric hernias occur along the linea alba. Spigelian hernias occur below the arcuate line where the inferior epigastric vessels traverse the fascia. Nerve roots passing through or around the lateral edge of the rectus sheath are often subject to irritation.

episodes were separated by months during which she felt well. Each episode started abruptly, without warning, and without a relationship to food. Previously, she had undergone computed tomographic (CT) scanning of the abdomen, barium radiography and endoscopy of the digestive tract, and endoscopic retrograde cholangiopancreatography. The findings of these studies were normal.

The patient was now admitted with acute right upper quadrant pain. A tender, fluctuant 8-cm mass was felt in the right upper quadrant, several centimeters inferior to a subcostal scar from a previous open cholecys-

tectomy. An abdominal CT scan was initially read as normal, but review of the scan showed herniation of omentum through a defect in the abdominal wall near the site of the cholecystectomy scar (*Figure 3*).

While the patient's right hip was being manipulated during a physical examination, her pain abruptly disappeared, along with the tender mass. A ventral hernia was diagnosed and surgically repaired.

#### DISCUSSION

As in the illustrative case, the area of tenderness in a ventral hernia may lie several cen-

timeters to the side of a visible surgical scar. The physical examination for a hernia should be performed with the patient both standing and supine. CT scanning is often useful in the evaluation of possible hernia, especially in obese patients.<sup>6</sup> However, it is important to focus the radiologist on the abdominal wall if the findings of the history and physical examination suggest a problem in this area, because it is not unusual for abdominal wall defects to be overlooked on CT scans.

#### OTHER LESIONS

Various lesions can cause acute or chronic pain in the abdominal wall. Localized tenderness often occurs in surgical scars several months after surgery because of the formation of neuromas. Endometriosis tends to recur in surgical scars.<sup>7,8</sup> Hematomas of the abdominal wall or rectus sheath can occur spontaneously or after surgery, trauma or pregnancy.<sup>9,10</sup> Desmoid tumors can also cause chronic abdominal pain.<sup>11</sup> Athletes have been found to develop abdominal wall pain related to myofascial tears or idiopathic intra-abdominal adhesions.<sup>12,13</sup>

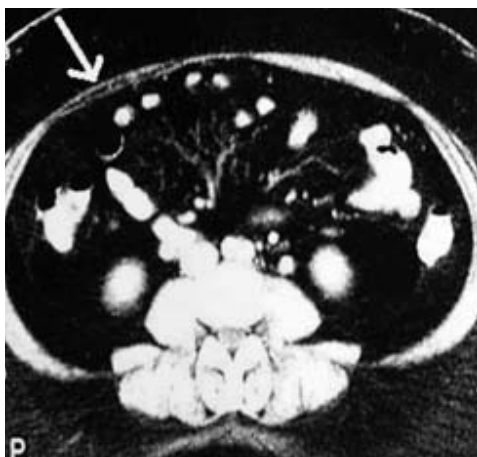


FIGURE 3. Abdominal computed tomographic scan showing a defect in the abdominal wall in the right upper quadrant (arrow). In this patient, omentum had become incarcerated in a ventral hernia inferior to an old cholecystectomy scar.

*The physical examination for a hernia should be performed with the patient both standing and supine.*

#### NEUROPATHIES

Herpes zoster can cause pain for days before the onset of vesicles. Painful acute neuropathy of the mononeuritis multiplex type can cause sudden, persistent abdominal pain in patients with diabetes or vasculitis. Nerve root irritation may result from the compression of nerve roots T7 through L1.<sup>14</sup> Nerve root compression can occur in or near the rectus sheath or can involve the ilioinguinal nerve.<sup>15-19</sup>

Common causes of abdominal wall pain are summarized in *Table 3*.

#### Idiopathic Abdominal Wall Pain

Many patients present with chronic pain that is not related to an identifiable mechanical or physiologic abnormality in the abdominal wall. Dealing with this ambiguous situation is somewhat similar to dealing with nonspecific low back pain, in that the exact structures and mechanisms responsible for the pain are often not known.

Pain trigger points frequently seem to lie along the lateral margins of the rectus abdominis muscles (linea semilunaris), where cutaneous nerve roots pass around the rectus sheath. It has been proposed that cutaneous nerve roots can become injured where they pass through the abdominal wall, perhaps by the stretching or compression of the nerve root along its course through the abdominal fascia.

In some instances, a tight belt or other poorly fitted clothing can cause nerve root irritation, especially in physically unfit persons with protuberant abdomens. Pain also can occur in or around the abdominal wall where muscles insert on bones or cartilage. For example, the pain can occur where the rectus abdominis muscles insert on the lower ribs or where the lower ribs connect through

**TABLE 3**  
**Etiology of Abdominal Wall Pain**

<i>Etiology</i>	<i>Comments</i>	<i>Diagnosis</i>
Hernia	Protuberance in abdominal wall that usually decreases in size when patient is supine	Abdominal CT scanning, abdominal ultrasonography, herniography
Rectus nerve entrapment	Occurs along lateral edge of rectus sheath; worsening of pain with tensing of muscles	Injection of local anesthetic
Thoracic lateral cutaneous nerve entrapment	Occurs spontaneously, after surgery or during pregnancy	History and physical examination
Ilioquinal and iliohypogastric nerve entrapment	Lower abdominal pain that occurs after inguinal hernia repair	History and physical examination
Endometriosis	Cyclic abdominal pain	Laparoscopy
Diabetic radiculopathy	Acute, severe truncal pain involving T6-T12 nerve roots	Paraspinal EMG
Abdominal wall tear	Occurs mainly in athletes	History and physical examination
Abdominal wall hematoma	Complication of abdominal laparoscopic procedures	Abdominal CT scanning, abdominal ultrasonography
Spontaneous rectus sheath hematoma	Presents as tender, usually unilateral mass that does not extend beyond midline	Abdominal CT scanning, abdominal ultrasonography
Desmoid tumor	Dysplastic tumor of connective tissue; occurs in young patients (females more often than males)	Surgical excision
Herpes zoster	Pain and hyperesthesia followed by vesicles along a dermatome	History and physical examination
Spinal nerve irritation	Caused by disorders of thoracic spine	CT scanning or MRI studies of thoracic spine
Slipping rib syndrome	Sharp, stabbing pain in upper abdomen caused by luxation of eighth to 10th ribs	Hooking maneuver to pull lower ribs anteriorly, which reproduces the pain and sometimes a click
Idiopathic	Myofascial pain	History and physical examination

*CT = computed tomography; EMG = electromyography; MRI = magnetic resonance imaging.*

cartilage. The xiphoid cartilage is sometimes a specific focus of pain.

Abdominal wall pain can be thought of as one category of myofascial pain. In this situation, muscle or fascial strain can lead to a pain trigger point. The mechanism for the pain may involve the development of an area of hyperalgesia as a result of myofascial stretch injury.<sup>20</sup>

## **Management**

### **PATIENT EDUCATION AND REASSURANCE**

Once a tentative diagnosis of abdominal wall pain has been made, it is important to explain the diagnosis to the patient. The patient may be worried about the implications of the pain. Furthermore, having to undergo a

long series of diagnostic tests may reinforce the patient's anxiety. In this setting, pain can take on a life of its own.

If there is evidence of a benign source of abdominal wall pain rather than a serious internal disease, reassurance should be provided. The physician can demonstrate how gentle palpation of the pain trigger point can reproduce the pain and its radiation over a wide area of the abdomen. The physician should explain that idiopathic abdominal wall pain is similar to idiopathic back or shoulder pain, in that the involved structure cannot be precisely described and the cause of the pain cannot be exactly identified.

#### TRIAL OF LOCAL ANESTHETIC

Much has been written about the treatment of idiopathic myofascial pain.<sup>20,21</sup> The trigger point for abdominal wall pain can be treated with injection of a small volume of local anesthetic. Once the patient identifies the trigger point with one finger, the physician "marches" his or her fingers around the area to identify the center of the tender spot, which is usually 1 to 2 cm in diameter.

A tuberculin syringe with a 5/8-inch needle is then used to inject a few tenths of a milliliter of 1 percent lidocaine (Xylocaine) into the most tender spot. A longer needle may be needed in an obese patient. The trigger point is identified when the tip of the needle causes marked tenderness.

The injection of local anesthetic serves as a therapeutic trial and may not provide permanent relief. However, a significant number of patients experience pain relief after one or two injections.<sup>5</sup> A major goal of trigger-point injection is to confirm the abdominal wall as the pain source. In addition, this simple maneuver can help persuade a skeptical patient that the abdominal wall is, indeed, the source of the pain.

#### LOCAL ANESTHETIC AND STEROID

For more permanent relief of pain, it is often useful to inject a mixture of local anesthetic and

*A major goal of trigger-point injection is to confirm the abdominal wall as the pain source.*

corticosteroid. Steroids presumably reduce inflammation or result in the thinning of connective tissue around painful nerve roots.

Only a few tenths of a milliliter of a 1:1 mixture of 1 or 2 percent lidocaine and triamcinolone (Aristocort, in a concentration of 40 mg per mL) is required (in any case, less than 1 mL), so less than 20 mg of triamcinolone is used. If the correct spot is injected, the pain should be relieved immediately, but it may return in a few hours when the effects of the lidocaine wear off. Triamcinolone may take effect slowly over a day or two and then provide long-term relief.

More than one injection may be required, given the hit-or-miss nature of this treatment. Such injections can be used to treat a tender trigger point in a surgical scar (a presumed neuroma). If reasonable care is taken, the risks associated with the injections should be minimal. Repeated injections or larger doses of the corticosteroid can cause thinning of the fascia and result in a hernia. For this reason, depot-type steroids should not be used in the fascia.

#### PHENOL

Permanent pain relief with anesthesia can be achieved with injections of phenol into the pain trigger point.<sup>22</sup> These injections should be given by an anesthesiologist or a pain treatment subspecialist. Referral to a subspecialist also may be considered for patients who have more generalized pain related to irritation of a thoracic or intercostal nerve root.

#### OTHER TREATMENTS

In addition to injection of medications, "dry" needling of pain trigger points without medication has been used with some success.<sup>23</sup> A trial of acupuncture or other alternative treatment might be considered.

Myofascial pain in the abdomen and elsewhere has also been treated using various combinations of massage, physical therapy with stretching, and cooling topical anesthetic sprays.<sup>20</sup> Warm soaks and other local methods can be useful.

### PSYCHOLOGIC DYSFUNCTION AND PAIN

If the distress caused by a patient's pain seems out of proportion to other findings, the presence of depression or other psychologic dysfunction should be considered. Pain that would normally be a minor nuisance can become the focus of somatization and be greatly magnified by depression.

A tricyclic antidepressant, given in a low dosage that minimizes sedation and anticholinergic side effects, can be helpful in providing pain relief.<sup>24</sup> Selective serotonin reuptake antagonists may be less effective than tricyclic antidepressants for the relief of chronic pain.

### Resources and Referrals

Family physicians should be able to diagnose and treat many patients with clear-cut, localized abdominal wall pain. Alternatively, patients can be referred to a pain treatment center or a pain treatment subspecialist. These resources can be located through organizations such as the American Pain Society (4700 W. Lake Ave., Glenview, IL 60025; telephone: 847-375-4715; Web site: [www.ampainsoc.org](http://www.ampainsoc.org)) or the American Academy of Pain Management (13947 Mono Way #A, Sonoma, CA 95370; telephone: 209-533-9744; Web site: [www.aapainmanage.org](http://www.aapainmanage.org)).

*The authors indicate that they do not have any conflicts of interest. Sources of funding: none reported.*

### REFERENCES

1. Hershfield NB. The abdominal wall. A frequently overlooked source of abdominal pain. *J Clin Gastroenterol* 1992;14:199-202.
2. Gallegos NC, Hobsley M. Abdominal wall pain: an alternative diagnosis. *Br J Surg* 1990;77:1167-70.
3. Thomson H, Francis DM. Abdominal-wall tenderness: a useful sign in the acute abdomen. *Lancet* 1977;2(8047):1053-4.
4. Thomson WH, Dawes RF, Carter SS. Abdominal wall tenderness: a useful sign in chronic abdominal pain. *Br J Surg* 1991;78:223-5.
5. Greenbaum DS, Greenbaum RB, Joseph JG, Natale JE. Chronic abdominal wall pain. Diagnostic validity and costs. *Dig Dis Sci* 1994;39:1935-41.
6. Rose M, Eliakim R, Bar-Ziv Y, Vromen A, Rachmilewitz D. Abdominal wall hernias. The value of computed tomography diagnosis in the obese patient. *J Clin Gastroenterol* 1994;19:94-6.
7. Wolf Y, Haddad R, Werbin N, Skornick Y, Kaplan O. Endometriosis in abdominal scars: a diagnostic pitfall. *Am Surg* 1996;62:1042-4.
8. Seydel AS, Sichel JZ, Warner ED, Sax HC. Extrapelvic endometriosis: diagnosis and treatment. *Am J Surg* 1996;171:239.
9. Edlow JA, Juang P, Margulies S, Burstein J. Rectus sheath hematoma. *Ann Emerg Med* 1999;34:671-5.
10. Moreno Gallego A, Aguayo JL, Flores B, Soria T, Hernandez Q, Ortiz S, et al. Ultrasonography and computed tomography reduce unnecessary surgery in abdominal rectus sheath haematoma. *Br J Surg* 1997;84:1295-7.
11. Ward SK, Roenigk HH, Gordon KB. Dermatologic manifestations of gastrointestinal disorders. *Gastroenterol Clin North Am* 1998;27:615-36.
12. Simonet WT, Saylor HL, Sim L. Abdominal wall muscle tears in hockey players. *Int J Sports Med* 1995;16:126-8.
13. Lauder TD, Moses FM. Recurrent abdominal pain from abdominal adhesions in an endurance triathlete. *Med Sci Sports Exerc* 1995;27:623-5.
14. Longstreth GF. Diabetic thoracic polyradiculopathy: ten patients with abdominal pain. *Am J Gastroenterol* 1997;92:502-5.
15. Peleg R, Gohar J, Koretz M, Peleg A. Abdominal wall pain in pregnant women caused by thoracic lateral cutaneous nerve entrapment. *Eur J Obstet Gynecol Reprod Biol* 1997;74:169-71.
16. Hall PN, Lee AP. Rectus nerve entrapment causing abdominal pain. *Br J Surg* 1988;75:917.
17. Hughes GS, Treadwell EL, Miller J. Syndrome of the rectus abdominis muscle mimicking the acute abdomen. *Ann Emerg Med* 1985;14:694-5.
18. Rutgers MJ. The rectus abdominis syndrome: a case report. *J Neurol* 1986;233:180-1.
19. Knockaert DC, D'Heygere FG, Bobbaers HJ. Ilioinguinal nerve entrapment: a little-known cause of iliac fossa pain. *Postgrad Med J* 1989;65:632-5.
20. Simons DG, Travell JG, Simons LS. Abdominal muscles. In: *Travell & Simons' Myofascial pain and dysfunction: the trigger point manual*. Vol. 1. Upper half of body. 2d ed. Baltimore: Williams & Wilkins, 1999:940-70.
21. Ling FW, Slocumb JC. Use of trigger point injections in chronic pelvic pain. *Obstet Gynecol Clin North Am* 1993;20:809-15.
22. Mehta M, Ranger I. Persistent abdominal pain. Treatment by nerve block. *Anaesthesia* 1971;26:330-3.
23. Hong CZ. Lidocaine injection versus dry needling to myofascial trigger point. The importance of the local twitch response. *Am J Phys Med Rehabil* 1994;73:256-63.
24. McQuay HJ, Moore RA. Antidepressants and chronic pain. *BMJ* 1997;314:763-4.