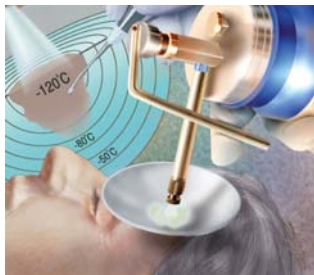

# Cryosurgery for Common Skin Conditions

MARK D. ANDREWS, M.D., Wake Forest University School of Medicine, Winston-Salem, North Carolina

Cryosurgery is a highly effective treatment for a broad range of benign skin problems. With appropriate instruction and supervised experience, family physicians can master the technique quickly. Cryosurgery is best suited for use in patients with light skin and for treatment of lesions in most non-hair-bearing areas of the body. Spray methods include the timed spot freeze technique, the rotary or spiral pattern, and the paintbrush method. Benign skin lesions that are suitable for freezing include actinic keratosis, solar lentigo, seborrheic keratosis, viral wart, molluscum contagiosum, and dermatofibroma. Cryosurgery requires little time and fits easily into the physician's office schedule. Advantages of this treatment include a short preparation time, low risk of infection, and minimal wound care. In addition, cryosurgery requires no expensive supplies or injectable anesthesia, and the patient does not have to return for suture removal. Potential side effects include bleeding, blister formation, headache, hair loss, and hypopigmentation, but rarely scarring. Skin lesions often can be treated in a single session, although some require several treatments. (*Am Fam Physician* 2004;69:2365-72. Copyright© 2004 American Academy of Family Physicians)



See page 2291 for definitions of strength-of-recommendation labels.

Cryosurgery has been used to treat skin lesions for approximately 100 years. The first cryogenes were liquid air<sup>1</sup> and compressed carbon dioxide snow.<sup>2</sup> Liquid nitrogen became available in the 1940s and currently is the most widely used cryogen.

Over the past 50 years, much experience has been gained in the use of cryosurgery to treat skin lesions.<sup>3</sup> The cotton-tipped dipstick method of liquid nitrogen application has been popular in the management of common benign lesions (*Figure 1,*

*left*). However, this method is being supplanted by liquid nitrogen spray techniques (*Figure 1, center*). Liquid nitrogen spray equipment (*Figure 2*) is easy to use, and similar techniques can be employed to manage benign, premalignant, and malignant lesions.

## Mechanism of Action

Liquid nitrogen, which boils at  $-196^{\circ}\text{C}$  ( $-320.8^{\circ}\text{F}$ ), is the most effective cryogen for clinical use. It is particularly useful in the treatment of malignant lesions. Temperatures of  $-25^{\circ}\text{C}$  to  $-50^{\circ}\text{C}$  ( $-13^{\circ}\text{F}$  to  $-58^{\circ}\text{F}$ ) can be achieved within 30 seconds if a sufficient amount of liquid nitrogen is applied by spray or probe. Generally, destruction of benign lesions requires temperatures of  $-20^{\circ}\text{C}$  to  $-30^{\circ}\text{C}$  ( $-4^{\circ}\text{F}$  to  $-22^{\circ}\text{F}$ ). Effective removal of malignant tissue often requires temperatures of  $-40^{\circ}\text{C}$  ( $-40^{\circ}\text{F}$ ) to  $-50^{\circ}\text{C}$ .

Irreversible damage in treated tissue occurs because of intracellular ice formation. The degree of damage depends on the rate of cooling and the minimum temperature achieved. Inflammation develops during the 24 hours after treatment, further contributing to destruction of the lesion through immunologically mediated mechanisms.

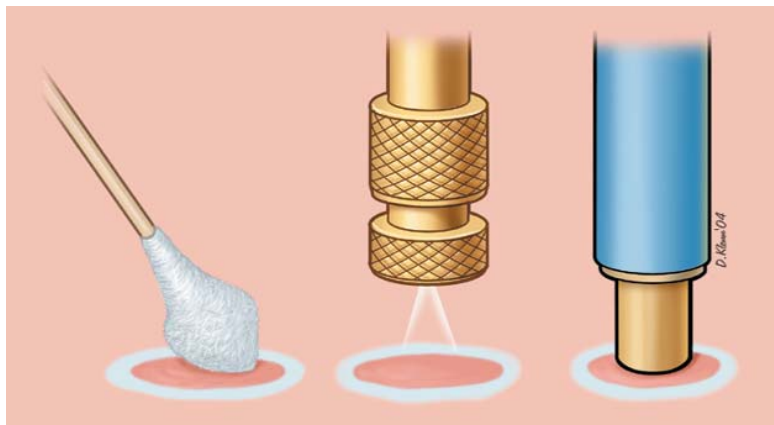


FIGURE 1. Cryosurgery devices. (*Left*) Cotton-tip applicator. (*Center*) Liquid nitrogen spray. (*Right*) Cryoprobe.

Continuous freezing at one location for more than 30 seconds beyond when an adequate freeze ball is achieved around the target area can result in disruption of the collagen matrix of the skin and possible scarring.



FIGURE 2. Liquid nitrogen spray equipment. (Left) Cryogun. (Right) Mini Cryogun.

Slow thaw times and repeat freeze-thaw cycles produce more tissue injury than a single freeze and thaw. Usually, several minutes are allowed between repeat freeze-thaw cycles. Repeat freeze-thaw cycles generally are employed only in the treatment of malignancy.

Continuous freezing at one location for more than 30 seconds beyond when an adequate freeze ball is achieved around the target

area can result in disruption of the collagen matrix of the skin and possible scarring.

Mild freezing leads to dermoepidermal separation, which is useful in treating benign epidermal lesions. The more sensitive cells in the epidermis are destroyed while the dermis is left intact. Treatment may be complicated by an element of hypopigmentation, but studies and clinical experience indicate that repigmentation often occurs over several months because of undamaged melanocytes within hair follicles or the migration of melanocytes from the edge of the frozen zone.<sup>4</sup> However, the predictability of repigmentation in individual patients is uncertain.

### Methods of Treatment

The dose of liquid nitrogen and the choice of delivery method depend on the size, tissue type, and depth of the lesion. The area of the body on which the lesion is located and the required depth of freeze also should be considered. Additional patient factors to consider include the thickness of the epidermis and underlying structures, the water content of the skin, and local blood flow.

Liquid nitrogen spray methods for lesions of different sizes include the timed spot freeze or direct spray technique, the rotary or spiral pattern, and the paintbrush method (Figure 3).

### TIMED SPOT FREEZE TECHNIQUE

The timed spot freeze technique allows greater standardization of liquid nitrogen delivery. It may be the most appropriate method for physicians who are learning to perform cryosurgery. Use of this technique maximizes the ability to destroy a lesion with minimal morbidity. The freezing time is adjusted according to variables such as skin thickness, vascularity, tissue type, and lesion characteristics.

Timed spot freezing is performed with a small spray gun that typically holds 300 to 500 mL of liquid nitrogen. Nozzle sizes range from A through F, with F representing the smallest aperture. Nozzle sizes B and C are

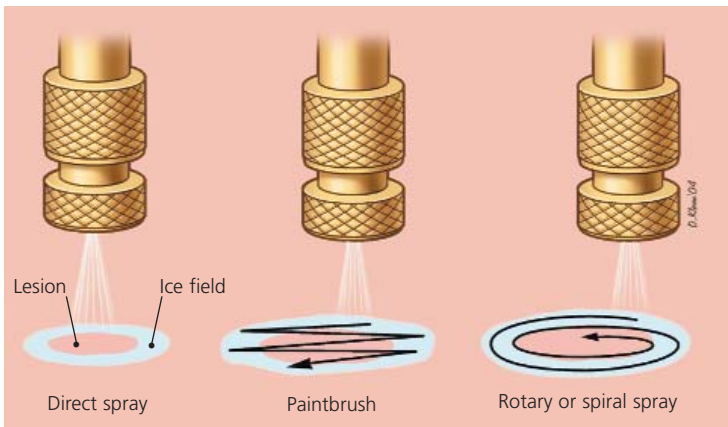


FIGURE 3. Liquid nitrogen spray patterns.

suitable for the treatment of most benign and malignant lesions; they are the apertures most frequently noted in case reports.

For the standard spot freeze technique, the nozzle of the spray gun is positioned 1 to 1.5 cm from the skin surface and aimed at the center of the target lesion (Figure 4). The spray gun trigger is depressed, and liquid nitrogen is sprayed until an ice field (or ice ball) encompasses the lesion and the desired margin (Figure 5). The designated ice field may need to be delineated in advance with a skin marker pen, because freezing may blur pretreatment lesion margins.

The margin size depends primarily on the thickness of the lesion and whether the lesion is benign or malignant. Margins for most benign lesions can extend as little as 1 to 2 mm beyond the visible pathologic border. Premalignant lesions need margins of 2 to 3 mm, while malignant lesions require margins of 5 mm of clinically normal skin to ensure adequate removal. These margin sizes allow enough depth of freeze to ensure temperatures of  $-50^{\circ}\text{C}$  to a depth of 4 to 5 mm.

Once the ice field has filled the specified margin, the spray needs to be maintained, with the spray canister trigger pressure and, thus, the liquid nitrogen spray flow adjusted to keep the target field frozen for an adequate time. This time may vary from five to 30 seconds beyond the initial time for formation of the ice field. If more than one freeze-thaw cycle is required for lesion destruction, complete thawing should be allowed before the next cycle (usually two to three minutes).

The timed spot freeze technique achieves temperatures that are adequate for tissue destruction in an ice field up to 2 cm in diameter. The best approach for lesions larger than 2 cm (including an adequate margin) is to use overlapping treatment fields. A detailed discussion of this approach is beyond the scope of this article.

#### OTHER TECHNIQUES

Variations on the open spray technique include the rotary or spiral pattern and the

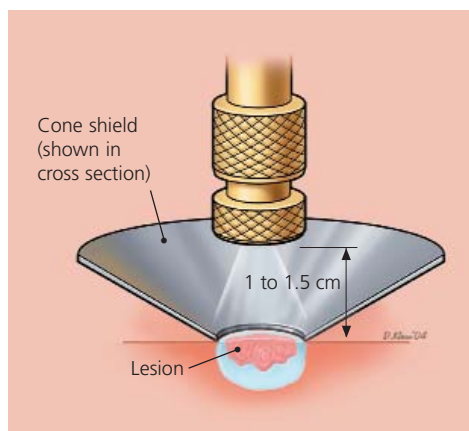


FIGURE 4. Liquid nitrogen spray application using a timed spot freeze technique and an open cone shield to direct the liquid nitrogen (note that an otoscope tip can be used with similar effect). The spray nozzle is positioned approximately 1 to 1.5 cm above the target lesion.

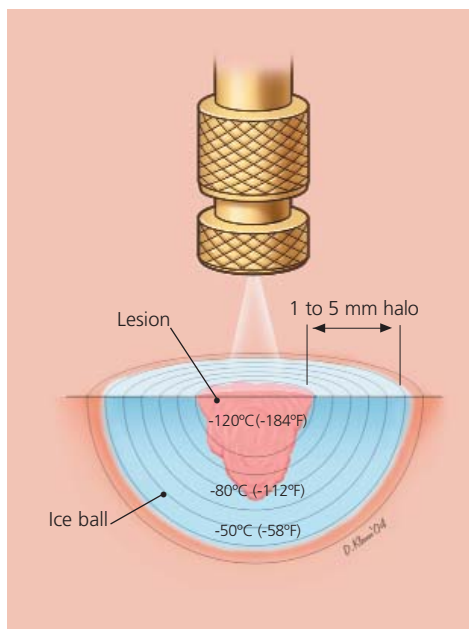


FIGURE 5. Timed spot freeze technique used to treat a malignancy (possibly a small basal cell cancer), demonstrating freeze ball formation and the 5-mm treatment margins necessary to achieve a temperature of  $-50^{\circ}\text{C}$  ( $-58^{\circ}\text{F}$ ) and, thus, the required depth of 4 to 5 mm.

*A gel interface medium often is used between the probe and the skin surface.*

paintbrush method. These techniques can be useful for treating larger benign lesions. They are not well standardized for ensuring the temperatures that are required for the destruction of malignant lesions.<sup>5,6</sup>


#### **CRYOPROBES**

While the open spray technique can be used for the most easily accessible lesions, a cryoprobe (*Figure 1, right*) attached to the liquid nitrogen spray gun can provide added versatility, depending on the site and type of the lesion. Various sizes and types of cryoprobes are available (*Figure 6*). The cryoprobe is applied directly to the lesions. A gel interface medium often is used between the probe and the skin surface.

Cryoprobes frequently are used in the treatment of smaller facial lesions (e.g., on the eyelids), where scatter of liquid nitrogen is undesirable. Probes also are useful in the management of vascular lesions, where the pressure of the probe can be used to remove blood from the tissues thus allowing more adequate treatment (*Figure 6*).

#### **Treatment of Benign Cutaneous Lesions**

Most benign skin lesions can be treated successfully with any of several treatment modalities (excision, cryosurgery, elec-



**FIGURE 6.** Mini Probe. The probe comes in different sizes (1 to 6 mm), with spray nozzles of variable aperture size.

trodesiccation curettage). However, cosmesis, cost, and patient convenience may make one treatment modality more desirable than another. Patients should be informed about all treatment options and should be allowed to choose from the reasonable alternatives.

For the conditions discussed in this article, cryosurgery has advantages over the other modalities. Preparation time is short, and treatment requires no expensive supplies or injectable anesthesia. In addition, the risk of infection is low, wound care is minimal, and suture removal is not needed.<sup>7</sup>

Correct clinical diagnosis and lesion selection are as critical as the timing of the liquid nitrogen spray in producing a favorable outcome. Depending on the type of lesion, standard technique may need to be varied. *Table 1* summarizes cryosurgery techniques for a variety of benign skin lesions.<sup>6,8-10</sup>

#### **SUN-DAMAGED SKIN**

Sun-damaged skin and related lesions are highly amenable to intervention with cryosurgical treatment. Localized small actinic keratosis, which is one of the most common solar-related skin abnormalities, usually requires only five to seven seconds of freeze time beyond initial appearance of a halo around the target lesion. Treatment requires only one freeze-thaw cycle and a margin of less than 1 mm.

#### **The Author**

MARK D. ANDREWS, M.D., is assistant professor in the Department of Family and Community Medicine and director of the residency training program at Wake Forest University School of Medicine, Winston-Salem, N.C. Dr. Andrews received his medical degree from the University of Maryland School of Medicine, Baltimore, and completed a family medicine residency at Washington Adventist Hospital, Takoma Park, Md.

*Address correspondence to Mark D. Andrews, M.D., Wake Forest University School of Medicine, Department of Family and Community Medicine, Piedmont Building, Medical Center Blvd., Winston-Salem, NC 27157-1084 (e-mail: mandrews@wfubmc.edu). Reprints are not available from the author.*

TABLE 1  
Recommended Cryosurgical Techniques

Type	Technique	Freeze time (seconds)*	Number of FTCs	Margin (mm)	Number of treatment sessions	Interval (weeks)†
Actinic keratosis	OS	5	1	1	1	
Cherry angioma	P	10	1	< 1	1	
Common warts	OS	10	1	2	3	4
Cutaneous horn	OS	10 to 15	1	2	1	
Dermatofibroma	P/OS	20 to 30	1	2	2	8
Hypertrophic scar	OS/P	20	1	2	1	
Ingrown toenail‡	OS	20	1	2	2	8
Keloid	OS/P	20 to 30	1	2	3	8
Myxoid cyst	OS/P	20	1	< 1	1	
Oral mucocele	P	10	1	< 1	1	
Pyogenic granuloma	OS	15	1	< 1	1	
Sebaceous hyperplasia	P	10	1	< 1	3	4
Skin tags	F/OS	5	1	2	1	
Solar lentigo	OS	5	1	< 1	1	

FTC = freeze-thaw cycle; OS = open spray; P = cryoprobe; F = forceps.

\*—Interval after the initial freeze ball or halo forms, not the total spray time.

†—Interval between repeat treatment sessions.

‡—Target is inflamed granulation tissue, and treatment is helpful in selected cases.

Information from references 6 and 8 through 10.

### SEBORRHEIC KERATOSIS

Seborrheic keratosis, the most common benign neoplasm, is best treated with cryosurgery or shave excision/curettage. Cryosurgery is especially effective in patients with multiple lesions.<sup>11</sup> Thin, flat lesions usually require only one five- to 10-second freeze-thaw cycle; larger, thicker lesions may need longer treatments times or, occasionally, two freeze-thaw cycles.

In treating seborrheic keratosis, the physician should consider the potential for hair loss in treated areas when choosing a therapeutic modality. The other major side effect of cryosurgery for this lesion is hypopigmentation. This side effect is more likely to occur in patients with dark skin.

### VIRAL SKIN INFECTIONS

Warts that are resistant to over-the-counter topical agents commonly are treated with cryosurgery. However, response is variable and often depends on the size of the wart and the

degree of hyperkeratosis. Several treatment sessions typically are required, and the overall success rate is approximately 75 percent.<sup>12,13</sup>

To avoid hypopigmentation, small flat warts may be treated with a light spray technique. Digital warts respond favorably to the timed spot freeze spray technique. Deep plantar or palmar warts present challenges, because pain may limit the patient's tolerance of freezing. However, favorable cure rates have been reported for initial pretreatment with keratolytics (salicylic acid).<sup>13</sup> The wart then can be shaved, and the base can be frozen with or without multiple freeze-thaw cycles.<sup>14</sup>

Cryosurgery has been found to be effective in the management of condyloma acuminatum, particularly when treatment with podophyllin (Podocon-25) has failed or the lesion is located in an area where use of this agent is undesirable.

Molluscum contagiosum, a common dermatologic problem in younger persons, is caused by a poxvirus. This lesion is amenable to cryosurgery, if indicated.<sup>15</sup> Applying liquid

TABLE 2

**Contraindications to Cryosurgery**

<b>Absolute contraindications</b>	<b>Relative contraindications</b>
Lesion for which tissue pathology is required*	Cold intolerance
Lesion located in an area with compromised circulation	Cold urticaria
Melanoma	Collagen disease or autoimmune disease
Patient unable to accept possibility of pigmentary changes	Concurrent treatment with immunosuppressive drugs
Proven sensitivity or adverse reaction to cryosurgery	Cryoglobulinemia
Sclerosing basal cell carcinoma or recurrent basal cell or squamous cell carcinoma, particularly when located in a high-risk area (e.g., temple, nasolabial fold)	Heavily pigmented skin
	Lesions located in pretibial areas, eyelid margins, nasolabial fold, ala nasi, and hair-bearing areas
	Multiple myeloma
	Pyoderma gangrenosum
	Raynaud's disease

\*—Biopsy must be performed before cryosurgery is considered.

TABLE 3

**Complications and Side Effects of Cryosurgery****Acute**

Bleeding at the freeze site  
Blister formation  
Edema  
Headache (after treatment of facial lesions)  
Pain  
Syncope (vasovagal; rare)

**Delayed**

Bleeding  
Excess granulation tissue formation (rare)  
Infection (rare)

**Protracted or permanent**

Atrophy (rare)  
Hair and hair follicle loss  
Hypopigmentation

**Protracted but temporary**

Alteration of sensation  
Hyperpigmentation  
Hypertrophic scarring  
Milia

nitrogen spray for a few seconds until the surface of the umbilicated papule turns white usually is adequate.

**DERMATOFIBROMA**

Open spray or cryoprobe techniques may be used to improve the cosmetic appearance of dermatofibromas. Surgical excision of these deep, asymptomatic skin nodules may result in hypertrophic scar formation, because the fibrous lesions are thought to arise from skin microtrauma.

A single 20- to 30-second freeze-thaw cycle is advised, and a 1- to 2-mm margin should be obtained. Retreatment in eight weeks may be necessary. Significant clinical improvement, including visible flattening of raised dermatofibromas and lightening of pigmentation, has been reported in 80 to 90 percent of patients.<sup>16</sup>

**Contraindications**

The relatively few contraindications to cryosurgery generally are related to concomitant illnesses in which excess reactions to cold may occur or delayed healing may be anticipated (*Table 2*). Some relative contraindications may make alternative treatment modalities more suitable. Physicians often do not perform cryosurgery in the pretibial areas, especially in elderly patients, because of slow wound healing.

**Complications**

Common complications and side effects of cryosurgery are listed in *Table 3*. Skin discomfort, generally a burning sensation, occurs with cryosurgery, but intensity is variable. The most sensitive areas are the fingertips, ears, and temples. Freezing of lesions on the forehead or temple may produce headaches. Treatment in hair-bearing areas can result in permanent hair loss.

Hypopigmentation is common, especially with longer freeze times, but is less noticeable in light-skinned patients and improves within several months. Hypopigmentation is caused by the greater sensitivity of melanocytes to

freezing, a situation that can be used to advantage in the treatment of dermatofibromas, which frequently have some mild overlying hyperpigmentation. Feathering of the freeze margin (lighter freeze area) often results in a better transition of pigmentary changes.

Freezing for less than 30 seconds beyond initial freeze ball formation does not result in scarring because of the preservation of fibroblasts and the collagen layer of the der-

mis, which allows for in-migration of the cellular components in the healing process and normal integrity of the skin layers.

Although rare and usually temporary, sensory nerve damage has been reported occasionally in large case series.<sup>17,18</sup> It may take 12 to 18 months for sensation to return.

Table 4<sup>19</sup> lists current procedural terminology billing codes that apply to cryosurgical techniques.

**TABLE 4**  
**CPT Codes Used in Cryosurgery for Benign Lesions\***

<i>CPT code</i>	<i>Procedure</i>
11200	Removal of skin tags, multiple fibrocuteaneous tags, any area; up to and including 15 lesions
11201†	Each additional 10 lesions (List separately in addition to code for primary procedure)
17000	Destruction (e.g., laser surgery, electrosurgery, cryosurgery, chemosurgery, surgical curettement), all benign or premalignant lesions (e.g., actinic keratoses) other than skin tags or cutaneous vascular proliferative lesions; first lesion
17003‡	Second through fourteenth lesions, each (List separately in addition to code for first lesion) (Use 17003 in conjunction with code 17000.)
17004‡	Destruction (e.g., laser surgery, electrosurgery, cryosurgery, chemosurgery, surgical curettement), all benign or premalignant lesions (e.g., actinic keratoses) other than skin tags or cutaneous vascular proliferative lesions; 15 or more lesions (Do not report 17004 in conjunction with codes 17000-17003.)
17110	Destruction (e.g., laser surgery, electrosurgery, cryosurgery, chemosurgery, surgical curettement), of flat warts, molluscum contagiosum, or milia; up to 14 lesions
17111	15 or more lesions (For destruction of common or plantar warts, see 17000, 17003, 17004)
46916	Destruction of lesion(s), anus (e.g., condyloma, papilloma, molluscum contagiosum, herpetic vesicle), simple; cryosurgery
46924	Destruction of lesion(s), anus (e.g., condyloma, papilloma, molluscum contagiosum, herpetic vesicle), extensive (e.g., laser surgery, electrosurgery, cryosurgery, chemosurgery)
54050	Destruction of lesion(s), penis (e.g., condyloma, papilloma, molluscum contagiosum, herpetic vesicle), simple; chemical
54056	Destruction of lesion(s), penis (e.g., condyloma, papilloma, molluscum contagiosum, herpetic vesicle), simple; cryosurgery
54065	Destruction of lesion(s), penis (e.g., condyloma, papilloma, molluscum contagiosum, herpetic vesicle), extensive (e.g., laser surgery, electrosurgery, cryosurgery, chemosurgery)
56501	Destruction of lesion(s), vulva; simple (e.g., laser surgery, electrosurgery, cryosurgery, chemosurgery)
56515	Destruction of lesion(s), vulva; extensive (e.g., laser surgery, electrosurgery, cryosurgery, chemosurgery)
67850	Destruction of lesion of lid margin (up to 1 cm)

*CPT = current procedural terminology.*

\*—Location and size of lesion not necessary unless otherwise indicated.

†—Add-on code.

‡—Modifier '-51' exempt.

*Adapted with permission from American Medical Association. Current procedural terminology: CPT 2002. Standard ed. Chicago: American Medical Association, 2001:48, 56, 144, 161, 167, 199. CPT is copyright© 2001 American Medical Association. All rights reserved. No fee schedules, basic units, relative values, or related listings are included in CPT. The AMA assumes no liability for data contained herein.*

**Strength of Recommendations**

<i>Key clinical recommendation</i>	<i>Strength of recommendation</i>	<i>Reference</i>
In the treatment of deep plantar or palmar warts, favorable cure rates have been reported for initial pretreatment with keratolytics (salicylic acid).	A	13
Molluscum contagiosum, a common dermatologic problem in younger persons, is caused by a poxvirus. This lesion is amenable to cryosurgery, if indicated.	C	15

*Figure 2 provided by Brymill Cryogenic Systems, Ellington, Conn. and Figure 6 provided by Mark D. Andrews, M.D.*

*The author indicates that he does not have any conflicts of interest. Sources of funding: none reported.*

**REFERENCES**

- White AC. Liquid air: Its application in medicine and surgery. *Med Rec* 1899;56:109-12.
- Pusey W. The use of carbon dioxide in the treatment of nevi and other lesions of the skin. *JAMA* 1907;49:1354-6.
- Zacarian SA. Cryogenics: The cryolesion and the pathogenesis of cryonecrosis. In: Zacarian SA, ed. *Cryosurgery for skin cancer and cutaneous disorders*. St. Louis: Mosby, 1985:1-30.
- Kuflik EG. Cryosurgery updated. *J Am Acad Dermatol* 1994;31:925-44.
- Lubritz RR. Cryo corner: cryosurgical spray patterns. *J Dermatol Surg Oncol* 1978;4(2):138-9.
- Dawber RP, Colver G, Jackson A. *Cutaneous cryosurgery: principles and clinical practice*. 2d ed. London: Martin Dunitz, 1997:28-36.
- Guidelines of care for cryosurgery. American Academy of Dermatology Committee on Guidelines of Care. *J Am Acad Dermatol* 1994;31:648-53.
- Cooper C. Cryotherapy in general practice [published correction appears in *Practitioner* 2001;245:1031]. *Practitioner* 2001;245:954-6.
- Hocutt J, Pfenninger JL. Cryosurgery. In: Pfenninger JL, Fowler GC, eds. *Pfenninger and Fowler's Procedures for primary care*. 2d ed. St. Louis: Mosby, 2003:97-112.
- Graham G. Cryosurgery for benign, premalignant, and malignant lesions. In: Wheeland RG, ed. *Cutaneous surgery*. Philadelphia: Saunders, 1994: 835-69.
- Luba MC, Bangs SA, Mohler AM, Stulberg DL. Common benign skin tumors. *Am Fam Physician* 2003;67:729-38.
- Lubritz RR. Cryosurgical approach to benign and precancerous tumors of the skin. In: Zacarian SA, ed. *Cryosurgery for skin cancer and cutaneous disorders*. St. Louis: Mosby, 1985:283-97.
- Gibbs S, Harvey I, Sterling JC, Stark R. Local treatments for cutaneous warts. *Cochrane Database Syst Rev* 2004;(1):CD001781.
- Prieto A. Cryosurgery for plantar and palmar verrucae. Presented at the Third International Symposium on Plastic Surgery of the Head and Neck, New Orleans, May 1979.
- Association for Genitourinary Medicine (AGUM), Medical Society for the Study of Venereal Disease (MSSVD). 2002 national guideline on the management of molluscum contagiosum. London: Association for Genitourinary Medicine (AGUM), Medical Society for the Study of Venereal Disease (MSSVD); 2002.
- Lanigan SW, Robinson TW. Cryotherapy for dermatofibromas. *Clin Exp Dermatol* 1987;12:121-3.
- Dawber RP. Cryosurgery: complications and contraindications. *Clin Dermatol* 1990;8:108-14.
- Heidenheim M, Jemec GB. Side effects of cryotherapy [Letter]. *J Am Acad Dermatol* 1991;24:653.
- American Medical Association. *Current procedural terminology: CPT 2002*. Standard ed. Chicago: American Medical Association, 2001:48, 56, 144, 161, 167, 199.