

Management of the Ingrown Toenail

JOEL J. HEIDELBAUGH, MD, and HOBART LEE, MD, *University of Michigan, Ann Arbor, Michigan*

Ingrown toenail, or onychocryptosis, most commonly affects the great toenail. Many anatomic and behavioral factors are thought to contribute to ingrown toenails, such as improper trimming, repetitive or inadvertent trauma, genetic predisposition, hyperhidrosis, and poor foot hygiene. Conservative treatment approaches include soaking the foot in warm, soapy water; placing cotton wisps or dental floss under the ingrown nail edge; and gutter splinting with or without the placement of an acrylic nail. Surgical approaches include partial nail avulsion or complete nail excision with or without phenolization. Electrocautery, radiofrequency, and carbon dioxide laser ablation of the nail matrix are also options. Oral antibiotics before or after phenolization do not improve outcomes. Partial nail avulsion followed by either phenolization or direct surgical excision of the nail matrix are equally effective in the treatment of ingrown toenails. Compared with surgical excision of the nail without phenolization, partial nail avulsion combined with phenolization is more effective at preventing symptomatic recurrence of ingrowing toenails, but has a slightly increased risk of postoperative infection. (*Am Fam Physician*. 2009;79(4):303-308, 311-312. Copyright © 2009 American Academy of Family Physicians.)

► **Patient information:** A handout on ingrown toenails, written by the authors of this article, is provided on page 311.

Approximately 20 percent of patients presenting to a family physician with a foot problem have an ingrown toenail, also known as onychocryptosis.¹ Ingrown toenails occur when the periungual skin is punctured by its corresponding nail plate, resulting in a cascade of foreign body, inflammatory, infectious, and reparative processes.² Ultimately, this may result in a painful, draining, and foul-smelling lesion of the involved toe (most commonly, the hallux nail), with soft tissue hypertrophy around the nail plate.

Causes and Risk Factors

Based on clinical experience, ingrown toenails are thought to be caused by improper

nail trimming or tearing nails off (*Figure 1*). Because of poor visualization or instrumentation, a barb is created that anchors itself in the soft periungual tissues and penetrates deeply as the nail plate grows distally. Force during ambulation, pressure from constricting footwear, and obesity (if present) drive the nail barb penetration and worsens its severity.²

Risk factors predisposing to development of ingrown toenails include anatomic and behavioral mechanisms. Some experts suggest that wider nail folds and thinner, flatter nails increase the risk of ingrown toenails,³ but this remains unproven. A case-control study with 46 patients found no difference in the anatomic shape of toenails in patients with and without ingrown toenails.⁴ Repetitive trauma (e.g., running, kicking) or inadvertent trauma (e.g., stubbing the toe) may be inciting factors.⁵

Without any strict evidence basis, it is thought that a genetic predisposition and family history,³ hyperhidrosis, and poor foot hygiene increase the likelihood of ingrown toenails.⁶ Diabetes, obesity, and thyroid, cardiac, and renal disorders that may predispose to lower extremity edema can also increase the likelihood.⁷

In adolescence, feet perspire more often, causing the skin and nails to become soft, resulting in easy splitting. This produces nail

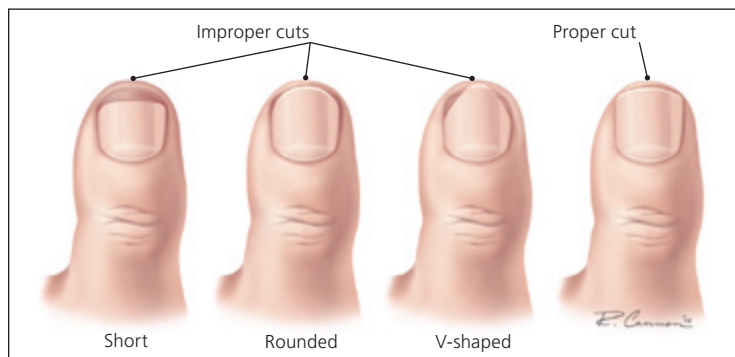


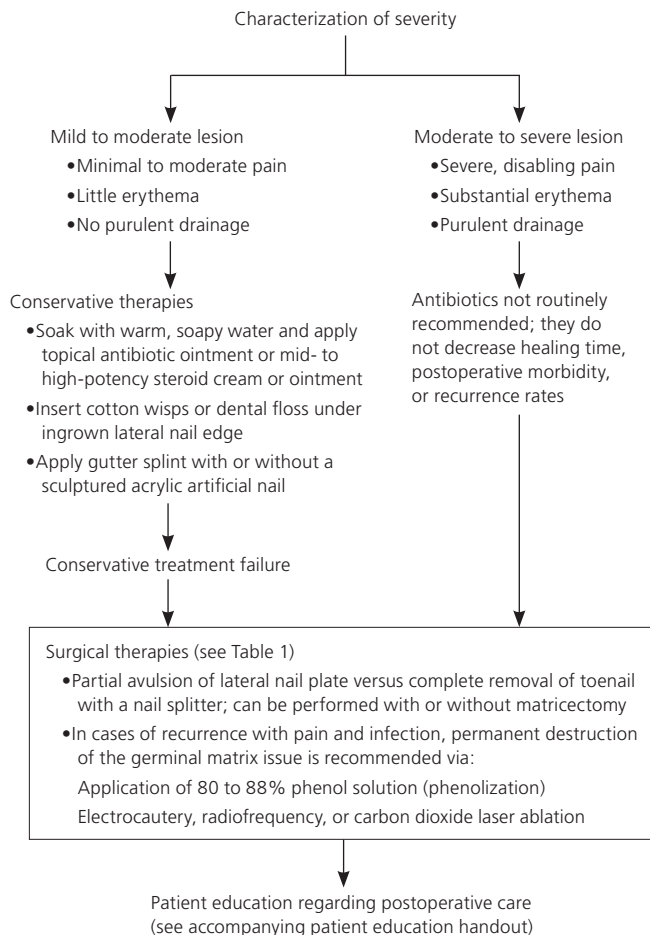
Figure 1. Examples of improper and proper toenail trimming. Toenails should be cut straight across, and the corners should not be rounded off.

SORT: KEY RECOMMENDATIONS FOR PRACTICE

Clinical recommendation	Evidence rating	References
Conservative approaches for the treatment of ingrown toenails without infection include placing a cotton wisp, dental floss, or gutter splint (with or without acrylic nail) under the ingrown nail edge.	C	12
Oral antibiotics before or after phenolization do not decrease healing rates or postprocedure morbidity in the treatment of ingrown toenails.	B	1
Partial nail avulsion followed by phenolization or direct surgical excision of the nail matrix are equally effective in the treatment of ingrown toenails.	B	16
Compared with surgical excision of the nail without phenolization, partial nail avulsion combined with phenolization is more effective at preventing symptomatic recurrence of ingrown toenails, but has a slightly increased risk of postoperative infection.	B	8

A = consistent, good-quality patient-oriented evidence; B = inconsistent or limited-quality patient-oriented evidence; C = consensus, disease-oriented evidence, usual practice, expert opinion, or case series. For information about the SORT evidence rating system, go to <http://www.aafp.org/afpsort.xml>.

Management of the Ingrown Toenail



spicules that can pierce the lateral skin. In older persons, spicule formation can become a chronic problem caused by their reduced ability to care for their nails secondary to reduced mobility or impaired vision. In addition, the natural aging process causes toenails to thicken, making them more difficult to cut and more inclined to exert pressure on the lateral skin at the sides of the nail plate, often becoming ingrown, painful, and infected.⁸

Presentation

Ingrown toenails are classified into three categories: mild, moderate, and severe. Mild cases are characterized by nail-fold swelling, erythema, edema, and pain with pressure. Moderate cases are associated with increased swelling, seropurulent drainage, infection, and ulceration of the nail fold. The most severe cases of ingrown toenail exhibit chronic inflammation and granulation, as well as marked nail-fold hypertrophy.^{9,10}

Treatment

Indications for the treatment of an ingrown toenail include significant pain or infection; onychogryposis (a deformed and curved nail); or chronic, recurrent paronychia (inflammation of the nail fold). Contraindications to surgical treatment include an allergy to local anesthetics (e.g., lidocaine [Xylocaine], bupivacaine [Marcaine]), a known bleeding diathesis, or pregnancy (in the case of phenol use).¹¹ Conservative and surgical treatment options exist and should be presented to the patient with respect to risks, benefits, alternatives, and patient preference (Figure 2).¹¹⁻¹⁷

Figure 2. Algorithm for a suggested approach to the patient with an ingrown toenail.

Information from references 1 and 11 through 17.

Conservative Therapy

Although clinical trials proving its value do not exist, conservative therapy is a reasonable approach in patients with a mild to moderate ingrown toenail who do not have significant pain, substantial erythema, or purulent drainage from the lateral nail edge. Conservative therapy provides a cost-effective approach that obviates the need for a minor surgical procedure and its attendant short-term minor disability and pain. One conservative treatment option is to soak the affected toe and foot for 10 to 20 minutes in warm, soapy water. After each soak, expert recommendation is to apply a topical antibiotic ointment (e.g., polymyxin/neomycin [Neosporin]) or a mid- to high-potency steroid cream or ointment to the affected area several times daily for a few days until resolution.¹²

Wisps of cotton placed under the ingrown lateral nail edge using a nail elevator or a small curette can also be attempted, with the patient repeating this process if the cotton falls out.¹² An uncontrolled case series found a 79 percent rate of symptomatic improvement using cotton wisps over a mean follow-up period of 24 weeks.¹³ There is no evidence to suggest that inserting cotton wisps underneath an ingrown nail edge harbors bacteria or potentially increases the risk of infection. Dental floss inserted obliquely under the ingrown nail corner has also been found to be effective in mild to moderate cases, producing minimal, if any, pain and no secondary infection, with almost immediate relief from pain and the ability to resume normal activities.¹⁴

Another conservative treatment approach is to use a gutter splint (e.g., a sterilized vinyl intravenous drip infusion tube slit from top to bottom with one end cut diagonally for smooth insertion) that can be affixed to the ingrown nail edge with either adhesive tape or a formable acrylic resin such as cyanoacrylate¹⁵ (Figure 3). A sculptured acrylic artificial nail can also be used in patients with an ingrown nail and no granulation tissue. A plastic nail platform is placed under the nail and fixed with adhesive tape. Formable acrylic is then placed on the nail and platform and molded into a nail shape to cover either a portion or the entire nail area surface. Treatment duration depends on the

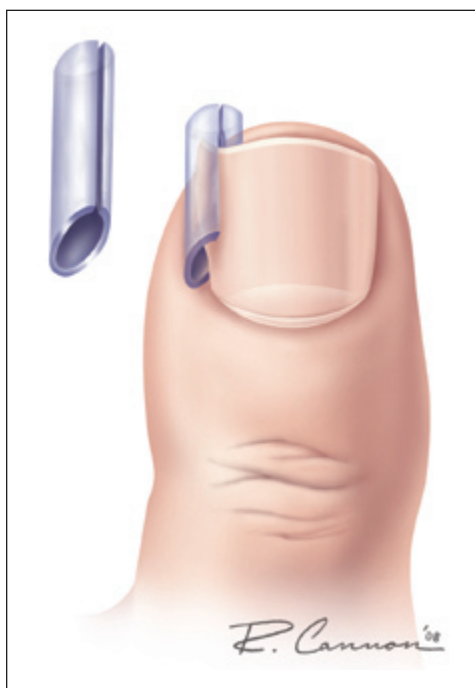

ILLUSTRATION BY RENEE CANNON

Figure 3. Gutter splint treatment for ingrown toenails.

time required for the normal nail to grow over the tip of the toe, which is approximately two weeks to three months.

Surgical Therapy

With proper training, family physicians can treat ingrown toenails without referral to a foot specialist. The most common procedure to treat locally infected ingrown toenails is partial avulsion of the lateral edge of the nail followed by chemical matricectomy using 80 to 88% phenol (phenolization).

ADJUNCTIVE ANTIBIOTICS

Infections of the lateral nail fold are most commonly caused by *Staphylococcus aureus* and less frequently by Gram-negative species (e.g., *Pseudomonas*) and *Streptococcus* species. Although the use of oral antibiotics before or after phenolization is widespread, their use is based solely upon historic practice without evidence from clinical trials. Several studies have indicated that once the ingrown portion of the nail is removed and matricectomy is performed, the localized infection will resolve without the need for antibiotic

Table 1. Surgical Approach to the Ingrown Toenail

1. Obtain surgical consent after explaining to the patient the risks, benefits, and alternatives. Place the patient in a supine or seated position with the affected toe (Figure 4) and foot hanging off the end of the table.
2. Prepare the affected toe with standard povidone iodine solution. Use lidocaine (Xylocaine) or bupivacaine (Marcaine) without epinephrine for local anesthesia in a digital block fashion.
3. Use a tourniquet or rubber band around the toe to assist in hemostasis for only a short duration; use with caution in patients with known peripheral vascular disease or diabetes (Figure 5).
4. Identify the lateral 20 to 25 percent of the ingrown nail as the site of the partial lateral nail avulsion. Use a nail elevator under the nail to separate it from the nail bed (Figure 6).
5. Use a nail splitter to cut from the distal end of the toenail straight back toward the cuticle beneath the nail fold (Figure 7).
6. Grasp the avulsed lateral nail fragment with a hemostat down to just past the cuticle. Remove it by twisting the avulsed nail outward toward the lateral nail fold while pulling in a straight direction toward the end of the toe. Ensure that the entire nail fragment and flat edge of the nail bed is retrieved to prevent formation of a nail spicule and the potential for recurrence of an ingrown nail.
7. Release the tourniquet after adequate hemostasis is achieved. Options for destruction of the nail-forming matrix beneath where the nail plate was removed include phenolization or mechanical destruction of the nail matrix. For phenolization, apply an 80 to 88% phenol solution directly to the nail matrix three times for 30 seconds each round (Figure 8). Then, thoroughly cleanse with 70% isopropyl alcohol to neutralize the phenol. Apply phenol only to the matrix and not the nail bed or surrounding tissue, which may delay wound healing. Phenol should not be used if the patient, physician, or medical assistants may be pregnant. Options for destruction of the nail matrix, as well as for removal of any adjacent granulation tissue, include electrocautery, radiofrequency, and carbon dioxide laser ablation.
8. After surgery, apply a dressing of antibiotic ointment (e.g., bacitracin/polymyxin [Polysporin]), 4 X 4 gauze, tube gauze, and paper tape, ensuring a comfortable bandage (variations on materials are acceptable; these recommendations are expert opinion).
9. After 24 to 48 hours, soak the affected toe in warm, soapy water and reapply antibiotic ointment and a clean bandage. This should be done three to four times daily for one to two weeks after the procedure.

Information from references 8, 12, and 17.

therapy.^{18,19} One randomized controlled trial with 54 patients found no significant difference in healing times between a group that received concomitant antibiotics and phenolization compared with a group that received phenolization alone over two to three weeks.¹ Initial treatment with oral antibiotics before surgical therapy has not been shown to decrease healing times and may delay matrixectomy in moderate to severe cases, which can ultimately increase the time until clinical healing.¹ Physicians should strongly consider withholding antibiotic treatment and proceeding to matrixectomy if conservative therapy is not an option.

DESTRUCTION OF THE MATRIX

Although phenol has antiseptic and anesthetic properties, it may cause tissue damage and possibly infection, delaying postoperative healing.²⁰ The best evidence demonstrates that partial nail avulsion followed by phenolization or direct surgical excision of the nail matrix are equally effective in the treatment of ingrown toenails.¹⁶ Another study found that partial nail avulsion with phenolization yielded better results than partial avulsion with nail matrix excision.²¹ In the latter study, local antibiotics did not reduce the risk of infection or recurrence of the ingrown toenail, and phenolization did not increase the risk of infection more than matrix excision.²¹ A Cochrane systematic review found that partial nail avulsion combined with phenolization is more effective at preventing symptomatic recurrence than surgical excision without phenolization, but has a slightly increased risk of postoperative infection.⁸ Trials evaluating different treatment methodologies have not adequately assessed patient satisfaction because follow-up time in each trial was less than six months, which is not an adequate time period to measure symptomatic recurrence. Although phenolization may be the most appropriate and beneficial treatment for most patients, risks and benefits should be discussed with each patient.

SURGICAL APPROACH

Unilateral matrixectomy is effective and appropriate in most cases, but contralateral ingrown toenail may develop over time as the remaining portion of the nail plate spontaneously repositions itself.²² Bilateral partial matrixectomy maintains the functional role of the nail plate (although narrowing it) and preserves its cosmetic role; therefore, it should be considered in patients with severe ingrown toenail or recurrences.²³ Excessive phenolization affecting adjacent tissues may cause serous oozing for up to five to six weeks after the procedure. The use of 20% ferric-chloride-soaked sterile cotton application for 20 to 30 seconds to the exposed nail bed has been found to reduce nail bed oozing, but carries a small risk of inducing local thrombosis.¹⁰

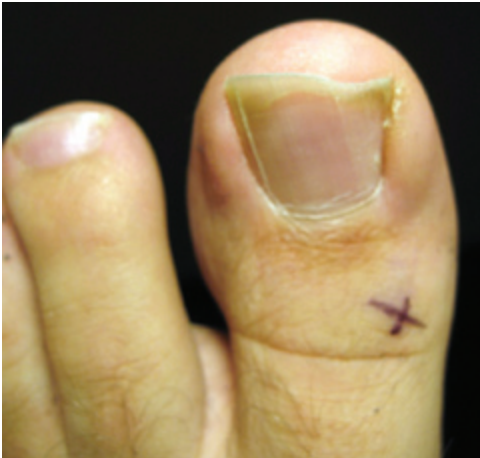

Figure 4. Ingrown left great toenail (medial right edge of the nail).

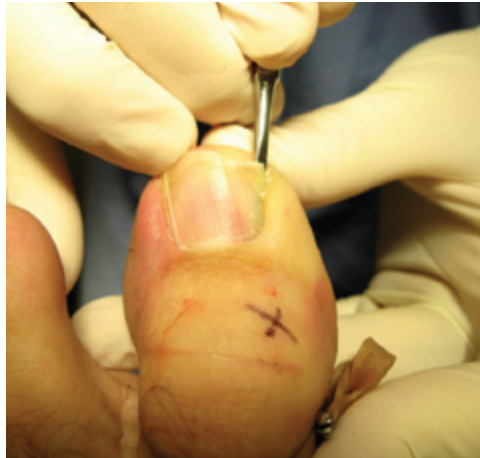

Figure 6. Separation of the nail from the nail bed with a nail elevator.

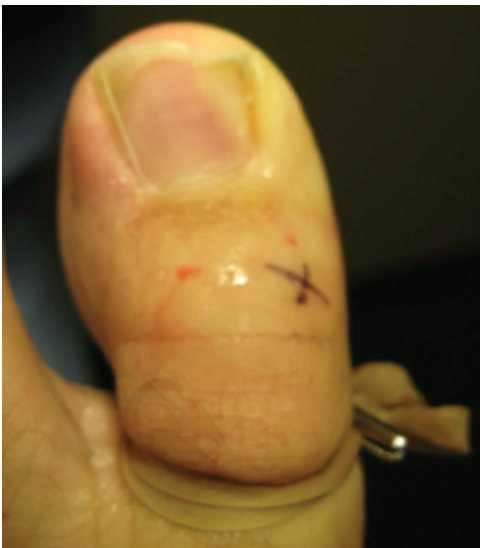

Figure 5. Application of tourniquet.

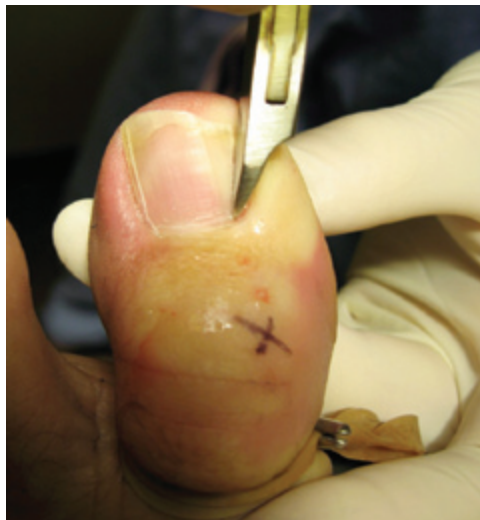

Figure 7. Cutting the ingrown portion of the nail with a nail splitter.

ALTERNATIVE PROCEDURES

Partial matricectomy via electrocautery, radiofrequency, and carbon dioxide laser ablation are all effective options in the treatment of ingrown toenails. Advantages of these techniques include less bleeding, reduced postoperative pain, and immediate sterilization of infected tissue. The carbon dioxide laser offers the advantage of limited thermal damage to adjacent tissues. Disadvantages include a commonly prolonged period for reepithelization and healing of the tissues by secondary intention and, consequently, local wound care for up to six weeks.²² Staining of the nail matrix with methylene blue before performing a partial matricectomy with the carbon dioxide laser allows for better visualization of the nail matrix and can ensure complete cauterization.²⁰ Matricectomy via

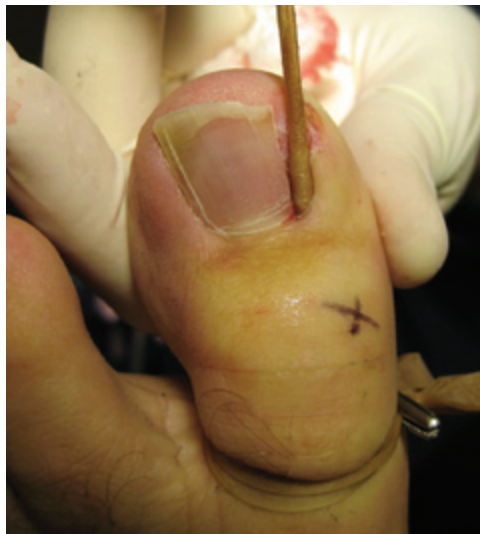

Figure 8. Application of phenol to the nail matrix.

these methods is more expensive because of the initial investment of equipment costs. To date, there have been no comparative trials to examine cost-effectiveness of either conservative or surgical treatment options.⁹

Approach to the Patient

Figure 2 provides a suggested approach to the patient with ingrown toenail.^{1,11-17} Table 1 summarizes the technical details of surgery.^{8,12,17}

Complications

An incomplete matricectomy can result in a regrowth of a nail spicule along the new lateral nail fold. This new nail growth results in an inflammatory reaction, often necessitating another procedure. If infection of the lateral nail fold is suspected, physicians should prescribe an oral antibiotic that covers common skin flora (e.g., cephalexin [Keflex] 500 mg orally four times daily for five to seven days).¹¹ Overaggressive electrocautery or radiofrequency ablation to the nail matrix may damage the adjacent and underlying fascia or periosteum. If the toe is healing poorly several weeks after the procedure, debridement, oral antibiotics, and radiographic evaluation may be warranted.¹²

Patients should be instructed before the procedure that the appearance of the affected nail will be permanently altered and that the recess created by the removal of the nail and granulation tissue will gradually resolve to a somewhat normal appearance.

The Authors

JOEL J. HEIDELBAUGH, MD, is a clinical assistant professor in the Departments of Family Medicine and Urology, and the clerkship director in the Department of Family Medicine at the University of Michigan, Ann Arbor. He received his medical degree from Upstate Medical University, and completed his residency at St. Joseph's Hospital Health Center, both in Syracuse, NY.

HOBART LEE, MD, is co-chief resident in the Department of Family Medicine at the University of Michigan. He received his medical degree from the University of Pennsylvania, Philadelphia.

Address correspondence to Joel J. Heidelbaugh, MD, Ypsilanti Health Center, 200 Arnet, Suite 200, Ypsilanti, MI 48198 (e-mail: jheidel@umich.edu). Reprints are not available from the authors.

Author disclosure: Nothing to disclose.

REFERENCES

- Reyzelman AM, Trombello KA, Vayser DJ, Armstrong DG, Harkless LB. Are antibiotics necessary in the treatment of locally infected ingrown toenails? *Arch Fam Med*. 2000;9(9):930-932.
- DeLauro NM, DeLauro TM. Onychocryptosis. *Clin Podiatr Med Surg*. 2004;21(4):617-630.
- Langford DT, Burke C, Robertson K. Risk factors in onychocryptosis. *Br J Surg*. 1989;76(1):45-48.
- Pearson HJ, Bury RN, Wapples J, Watkin DF. Ingrowing toenails: is there a nail abnormality? A prospective study. *J Bone Joint Surg Br*. 1987;69(5):840-842.
- Yang KC, Li YT. Treatment of recurrent ingrown great toenail associated with granulation tissue by partial nail avulsion followed by matricectomy with sharpulse carbon dioxide laser. *Dermatol Surg*. 2002;28(5):419-421.
- Ikard RW. Onychocryptosis. *J Am Coll Surg*. 1998;187(1):96-102.
- Scher RK. Toenail disorders. *Clin Dermatol*. 1983;1(1):114-124.
- Rounding C, Bloomfield S. Surgical treatments for ingrowing toenails. *Cochrane Database Syst Rev*. 2005;(2):CD001541.
- Aksakal AB, Atahan C, Oztas P, Oruk S. Minimizing postoperative drainage with 20% ferric chloride after chemical matricectomy with phenol. *Dermatol Surg*. 2001;27(2):158-160.
- Ozdemir E, Bostanci S, Ekmekci P, Gurgey E. Chemical matricectomy with 10% sodium hydroxide for treatment of ingrowing toenails. *Dermatol Surg*. 2004;30(1):26-31.
- Peggs JF. Ingrown toenails. In: Pfenninger JL and Fowler GC. *Pfenninger and Fowler's Procedures for Primary Care*. 2d ed. St. Louis, Mo.: Mosby;2003:269-272.
- Daniel CR III, Iorizzo M, Tosti A, Piraccini BM. Ingrown toenails. *Cutis*. 2006;78(6):407-408.
- Senapati A. Conservative outpatient management of ingrowing toenails. *J R Soc Med*. 1986;79(6):339-340.
- Woo SH, Kim IH. Surgical pearl: nail edge separation with dental floss for ingrown toenails. *J Am Acad Dermatol*. 2004;50(6):939-940.
- Arai H, Arai T, Nakajima H, Haneke E. Formable acrylic treatment for ingrowing nail with gutter splint and sculptured nail. *Int J Dermatol*. 2004;43(10):759-765.
- Gerritsma-Bleeker CL, Klaase JM, et al. Partial matrix excision or segmental phenolization for ingrowing toenails. *Arch Surg*. 2002;137(3):320-325.
- Zuber TJ. Ingrown toenail removal. *Am Fam Physician*. 2002;65(12):2547-2552, 2554.
- Monheit GD. Nail surgery. *Dermatol Clin*. 1985;3(3):521-530.
- Brown FC. Chemocautery of ingrown toenails. *J Dermatol Surg Oncol*. 1981;7(4):331-333.
- Ozawa T, Nose K, Harada T, et al. Partial matricectomy with a CO2 laser for ingrown toenail after nail matrix staining. *Dermatol Surg*. 2005;31(3):302-305.
- Bos AMC, van Tilburg MW, et al. Randomized clinical trial of surgical technique and local antibiotics for ingrowing toenail. *Br J Surg*. 2007;94(3):292-296.
- Serour F. Recurrent ingrown big toenails are efficiently treated by CO2 laser. *Dermatol Surg*. 2002;28(6):509-512.
- Siegle RJ, Stewart R. Recalcitrant ingrown nails. Surgical approaches. *J Dermatol Surg Oncol*. 1992;18(8):744-752.