

Splints and Casts: Indications and Methods

ANNE S. BOYD, MD, *University of Pittsburgh School of Medicine, Pittsburgh, Pennsylvania*

HOLLY J. BENJAMIN, MD, *University of Chicago, Chicago, Illinois*

CHAD ASPLUND, MD, *The Ohio State University College of Medicine, Columbus, Ohio*

Management of a wide variety of musculoskeletal conditions requires the use of a cast or splint. Splints are noncircumferential immobilizers that accommodate swelling. This quality makes splints ideal for the management of a variety of acute musculoskeletal conditions in which swelling is anticipated, such as acute fractures or sprains, or for initial stabilization of reduced, displaced, or unstable fractures before orthopedic intervention. Casts are circumferential immobilizers. Because of this, casts provide superior immobilization but are less forgiving, have higher complication rates, and are generally reserved for complex and/or definitive fracture management. To maximize benefits while minimizing complications, the use of casts and splints is generally limited to the short term. Excessive immobilization from continuous use of a cast or splint can lead to chronic pain, joint stiffness, muscle atrophy, or more severe complications (e.g., complex regional pain syndrome). All patients who are placed in a splint or cast require careful monitoring to ensure proper recovery. Selection of a specific cast or splint varies based on the area of the body being treated, and on the acuity and stability of the injury. Indications and accurate application techniques vary for each type of splint and cast commonly encountered in a primary care setting. This article highlights the different types of splints and casts that are used in various circumstances and how each is applied. (*Am Fam Physician*. 2009;80(5):491-499. Copyright © 2009 American Academy of Family Physicians.)



The online version of this article includes supplemental content at <http://www.aafp.org/afp>.

Family physicians often make decisions about the use of splints and casts in the management of musculoskeletal disorders. Because of this, they need to be familiar with indications for application, proper technique, and the potential pitfalls of casting and splinting to optimize patient care when treating common orthopedic injuries.

Splints and casts immobilize musculoskeletal injuries while diminishing pain and promoting healing; however, they differ in their construction, indications, benefits, and risks. When determining whether to apply a splint or a cast, the physician must make an accurate diagnosis, as well as assess the stage, severity, and stability of the injury; the patient's functional requirements; and the risk of complications (*Table 1*).^{1,2}

Because splints are noncircumferential immobilizers and are, therefore, more forgiving, they allow for swelling in the acute phase. Splinting is useful for a variety of acute orthopedic conditions such as fractures, reduced joint dislocations, sprains, severe soft tissue injuries, and post-laceration repairs. The purpose of splinting acutely is to immobilize and protect the injured extremity, aid in healing, and lessen pain. Splinting

during the later phases of injury or for chronic conditions will assist with healing, long-term pain control, and progression of physical function, and it will slow progression of the pathologic process.^{3,4}

Casting involves circumferential application of plaster or fiberglass to an extremity. Casts provide superior immobilization, but are less forgiving and have higher complication rates. Therefore, they are usually reserved for complex and/or definitive fracture management.

Application of any immobilizer comes with potential complications, including ischemia, heat injury, pressure sores, skin breakdown, infection, dermatitis, neurologic injury, and compartment syndrome. These conditions can occur regardless of how long the device is used.⁵ To maximize benefits while minimizing complications, the use of casts and splints is generally limited to the short term. Excessive immobilization from continuous use of a cast or splint can lead to chronic pain, joint stiffness, muscle atrophy, or more severe complications, such as complex regional pain syndrome.⁶ All patients who are placed in a splint or cast require careful monitoring to ensure proper recovery.⁷

SORT: KEY RECOMMENDATIONS FOR PRACTICE

<i>Clinical recommendation</i>	<i>Evidence rating</i>	<i>References</i>	<i>Comments</i>
Use of a short arm radial gutter splint is recommended for initial immobilization of a displaced distal radial fracture.	B	11	RCT
Immobilization of the thumb with a removable splint after a ligamentous injury is strongly preferred by patients, and the functional results are equal to those of plaster cast immobilization after surgical and nonsurgical treatment.	B	12	RCT
Removable splinting is preferable to casting in the treatment of wrist buckle fractures in children.	B	13	RCT
Evidence supports a functional treatment approach to inversion ankle sprains with the use of a semirigid or soft lace-up brace.	B	17	Systematic review

RCT = randomized controlled trial.

A = consistent, good-quality patient-oriented evidence; *B* = inconsistent or limited-quality patient-oriented evidence; *C* = consensus, disease-oriented evidence, usual practice, expert opinion, or case series. For information about the SORT evidence rating system, go to <http://www.aafp.org/afpsort.xml>.

Cast/Splint Choice and Application

This article highlights the different types of splints and casts that are used in various circumstances and how each is applied. In a previous article in *American Family Physician*, we discussed the principles and risks of casting and splinting, as well as proper techniques for safe application.⁶

Casting and splinting both begin by placing the injured extremity in its position of function. Casting continues with application of stockinette, then circumferential application of two or three layers of cotton padding, and finally circumferential application of plaster or fiberglass. In general, 2-inch padding is used for the hands, 2- to 4-inch padding for the upper extremities, 3-inch padding for the feet, and 4- to 6-inch padding for the lower extremities.

Splinting may be accomplished in a variety of ways. One option is to begin as if creating a cast and, with the

extremity in its position of function, apply stockinette, then a layer of overlapping circumferential cotton padding. The wet splint is then placed over the padding and molded to the contours of the extremity, and the stockinette and padding are folded back to create a smooth edge (*Figure 1*). The dried splint is secured in place by wrapping an elastic bandage in a distal to proximal direction. For an average-size adult, upper extremities should be splinted with six to 10 sheets of casting material, whereas lower extremities may require 12 to 15 sheets.

An acceptable alternative is to create a splint without the use of stockinette or circumferential padding. Several layers of padding that are slightly wider and longer than the splint are applied directly to the smoothed, wet splint. Together they are molded to the extremity and secured with an elastic bandage (*Figure 2*). Prepackaged splints consisting of fiberglass and padding wrapped in a

Table 1. Comparison of Splints and Casts

<i>Splint/cast</i>	<i>Construction</i>	<i>Indications</i>	<i>Advantages</i>	<i>Risks/disadvantages</i>
Splint	Noncircumferential	Acute and definitive treatment of select fractures Soft tissue injuries (sprains, tendons) Acute management of injuries awaiting orthopedic intervention	Allows for acute swelling Decreased risk of complications Faster and easier application Commercial splints available and appropriate for select injuries May be static (preventing motion) or dynamic (functional; assisting with controlled motion)	Lack of compliance Increased range of motion at injury site Not useful for definitive care of unstable or potentially unstable fractures
Cast	Circumferential	Definitive management of simple, complex, unstable, or potentially unstable fractures Severe, nonacute soft tissue injuries unable to be managed with splinting	More effective immobilization	Higher risk of complications More technically difficult to apply

Information from references 1 and 2.

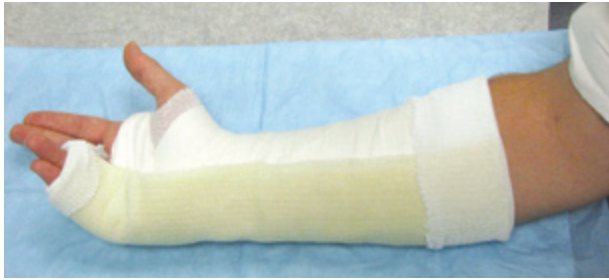

Figure 1. Ulnar gutter splint with underlying stockinette and circumferential padding.

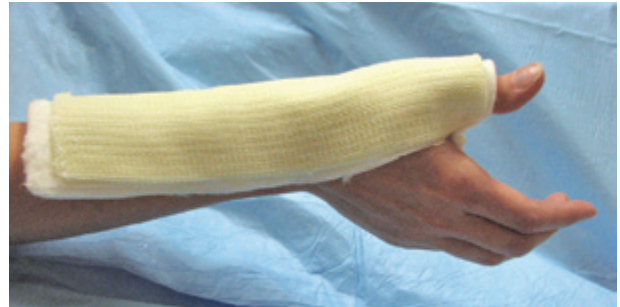

Figure 2. Padded thumb spica splint.

mesh layer also exist. These are easily cut and molded to the injured extremity; however, they are more expensive and are not always available. Prefabricated and over-the-counter splints are the simplest option, although they are less “custom fit,” and their use may be limited by cost or availability.

The most common types of splints and casts used in primary care, with information on indications and follow-up, are discussed in *Tables 2 through 4*. All splints are described before elastic bandage application.

GENERAL FRACTURE MANAGEMENT PRINCIPLES

It is important to maintain good anatomic fracture alignment throughout treatment. Acceptable angular deformity in the hand varies depending on the fracture site. Rotational deformity in the hand is never acceptable.

Stable fractures are generally reevaluated within one to two weeks following cast application to assess cast fit and condition, and to perform radiography to monitor healing and fracture alignment. Hand and forearm fractures, however, are often reevaluated within the first week.

Displaced fractures require closed reduction, followed by post-reduction radiography to confirm bone alignment. Both displaced and unstable fractures should be monitored vigilantly to ensure maintained positioning. If reduction or positioning is not maintained, urgent referral to an orthopedic subspecialist is warranted.⁸⁻¹⁰

Upper Extremity Splints and Casts

ULNAR GUTTER SPLINT

Common Uses. Nondisplaced, stable fractures of the head, neck, and shaft of the fourth or fifth metacarpal with mild angulation and no rotational deformities; nondisplaced, nonrotated shaft fractures and serious soft tissue injuries of the fourth or fifth, proximal or middle phalanx; boxer’s fractures (distal fifth metacarpal fractures, the most common injury for which ulnar gutter splint/cast used).

Application. The splint begins at the proximal forearm and extends to just beyond the distal interphalangeal (DIP) joint (*Figure 1*). Cast padding is placed between the fingers.

Position of Function. The wrist is slightly extended, with the metacarpophalangeal (MCP) joints in 70 to 90 degrees of flexion, and the proximal interphalangeal (PIP) and DIP joints in 5 to 10 degrees of flexion.

ULNAR GUTTER CAST

Common Uses. Definitive or alternative treatment of injuries commonly treated with ulnar gutter splint.⁸

Application. Ideally, the cast is applied 24 to 48 hours or more after the initial injury to allow swelling to decrease. Placement of the casting materials is similar to that of the ulnar gutter splint, except the plaster or fiberglass is wrapped circumferentially (*Figure 3*).

RADIAL GUTTER SPLINT

Common Uses. Nondisplaced fractures of the head, neck, and shaft of the second or third metacarpal without angulation or rotation; nondisplaced, nonrotated shaft fractures and serious injuries of the second or third, proximal or middle phalanx; initial immobilization of displaced distal radius fractures.¹¹

Application. The splint runs along the radial aspect of the forearm to just beyond the DIP joint of the index

Table 2. Commonly Used Splints and Casts

Area of injury	Type of splint	Type of cast
Hand/finger	Ulnar gutter, radial gutter, thumb spica, finger	Ulnar gutter, radial gutter, thumb spica
Forearm/wrist	Volar/dorsal forearm, single sugar-tong	Short arm, long arm
Elbow/forearm	Long arm posterior, double sugar-tong	Long arm
Knee	Posterior knee, off-the-shelf immobilizer	Long leg
Tibia/fibula	Posterior ankle (mid-shaft and distal fractures), bulky Jones	Long leg (proximal fracture), short leg (mid-shaft and distal)
Ankle	Posterior ankle (“post-mold”), stirrup, bulky Jones, high-top walking boot	Short leg
Foot	Posterior ankle with or without toe box, hard-soled shoe, high-top walking boot	Short leg, short leg with toe box for phalanx fracture


Table 3. Upper Extremity Splinting and Casting Chart

<i>Region</i>	<i>Type of splint/cast</i>	<i>Indications</i>	<i>Pearls/pitfalls</i>	<i>Follow-up/referral</i>
Ulnar side of hand	Ulnar gutter splint/cast	Fourth and fifth proximal/middle phalangeal shaft fractures and select metacarpal fractures	Proper positioning of MCP joints at 70 to 90 degrees of flexion, PIP and DIP joints at 5 to 10 degrees of flexion	One to two weeks Refer for angulated, displaced, rotated, oblique, or intra-articular fracture or failed closed reduction
Radial side of hand	Radial gutter splint/cast	Second and third proximal/middle phalangeal shaft fractures and select metacarpal fractures	Proper positioning of MCP joints at 70 to 90 degrees of flexion, PIP and DIP joints at 5 to 10 degrees of flexion	One to two weeks Refer for angulated, displaced, rotated, oblique, or intra-articular fracture or failed closed reduction
Thumb, first metacarpal, and carpal bones	Thumb spica splint/cast	Injuries to scaphoid/trapezium Nondisplaced, nonangulated, extra-articular first metacarpal fractures Stable thumb fractures with or without closed reduction	Fracture of the middle/proximal one third of the scaphoid treated with casting	One to two weeks Refer for angulated, displaced, intra-articular, incompletely reduced, or unstable fracture Refer displaced fracture of the scaphoid
Finger injuries	Buddy taping	Nondisplaced proximal/middle phalangeal shaft fracture and sprains	Encourage active range of motion in all joints	Two weeks Refer for angulated, displaced, rotated, oblique, or significant intra-articular fracture or failure to regain full range of motion
	Aluminum U-shaped splint	Distal phalangeal fracture	Encourage active range of motion at PIP and MCP joints	
	Dorsal extension-block splint	Middle phalangeal volar plate avulsions and stable reduced PIP joint dislocations	Increase flexion by 15 degrees weekly, from 45 degrees to full extension Buddy taping permitted with splint use	
	Mallet finger splint	Extensor tendon avulsion from the base of the distal phalanx	Continuous extension in the splint for six to eight weeks is essential	
Wrist/hand	Volar/dorsal forearm splint	Soft tissue injuries to hand and wrist Acute carpal bone fractures (excluding scaphoid/trapezium) Childhood buckle fractures of the distal radius	Consider splinting as definitive treatment for buckle fractures	One week Refer for displaced or unstable fractures Refer lunate fractures
	Short arm cast	Nondisplaced, minimally displaced, or buckle fractures of the distal radius Carpal bone fractures other than scaphoid/trapezium		
Forearm	Single sugar-tong splint	Acute distal radial and ulnar fractures	Used for increased immobilization of forearm and greater stability	Less than one week Refer for displaced or unstable fractures
Elbow, proximal forearm, and skeletally immature wrist injuries	Long arm posterior splint, long arm cast	Distal humeral and proximal/midshaft forearm fractures Nonbuckle wrist fractures	Ensure adequate padding at bony prominences	Within one week Refer for displaced or unstable fractures
	Double sugar-tong splint	Acute elbow and forearm fractures, and nondisplaced, extra-articular Colles fractures	Offers greater immobilization against pronation/supination	Less than one week Refer childhood distal humeral fractures

DIP = distal interphalangeal; MCP = metacarpophalangeal; PIP = proximal interphalangeal.

Table 4. Lower Extremity Splinting and Casting Chart

Region	Type of splint/cast	Indications	Pearls/pitfalls	Follow-up/referral
Ankle	Posterior ankle splint ("post-mold")	Severe sprains Isolated, nondisplaced malleolar fractures Acute foot fractures	Splint ends 2 inches distal to fibular head to avoid common peroneal nerve compression	Less than one week Refer for displaced or multiple fractures or significant joint instability
Ankle	Stirrup splint	Ankle sprains Isolated, nondisplaced malleolar fractures	Mold to site of injury for effective compression	Less than one week
Lower leg, ankle, and foot	Short leg cast	Isolated, nondisplaced malleolar fractures Foot fractures—tarsals and metatarsals	Compartment syndrome most commonly associated with proximal mid-tibial fractures, so care is taken not to over-compress Weight-bearing status important; initially non-weight bearing with tibial injuries	Two to four weeks Refer for displaced or angulated fracture or proximal first through fourth metatarsal fractures
Knee and lower leg	Posterior knee splint	Acute soft tissue and bony injuries of the lower extremity	If ankle immobilization is necessary, as with tibial shaft injuries, the splint should extend to include the metatarsals	Days
Foot	Short leg cast with toe plate extension	Distal metatarsal and phalangeal fractures	Useful technique for toe immobilization Often used when high-top walking boots are not available	Two weeks Refer for displaced or unstable fractures

 finger, leaving the thumb free (*Online Figure A*). Cast padding is placed between the fingers.

Position of Function. The wrist is placed in slight extension, with the MCP joints in 70 to 90 degrees of flexion, and the PIP and DIP joints in 5 to 10 degrees of flexion.

RADIAL GUTTER CAST

Common Uses. Definitive or alternative treatment of fractures initially managed with a radial gutter splint.

Application. Placement of the casting materials is similar to that of the radial gutter splint, except the plaster

or fiberglass is wrapped circumferentially (*Figure 4*). The cast is usually placed two to seven days after the initial injury to allow for resolution of swelling.

Pearls and Pitfalls. Minimal angulation or rotation at the fracture site may cause functional problems, such as difficulty with grasp, pinch, or opposition. Therefore, meticulous evaluation and follow-up are essential.

THUMB SPICA SPLINT

Common Uses. Suspected injuries to the scaphoid; stable ligamentous injuries to the thumb; initial treatment of nonangulated, nondisplaced, extra-articular fractures

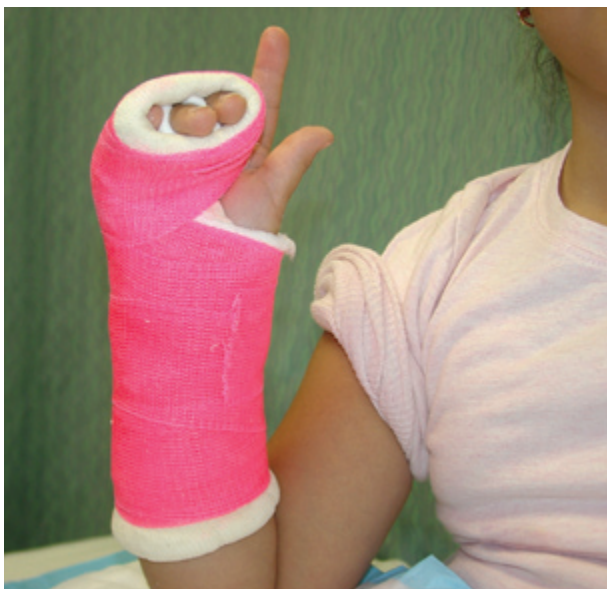

Figure 3. Ulnar gutter cast.

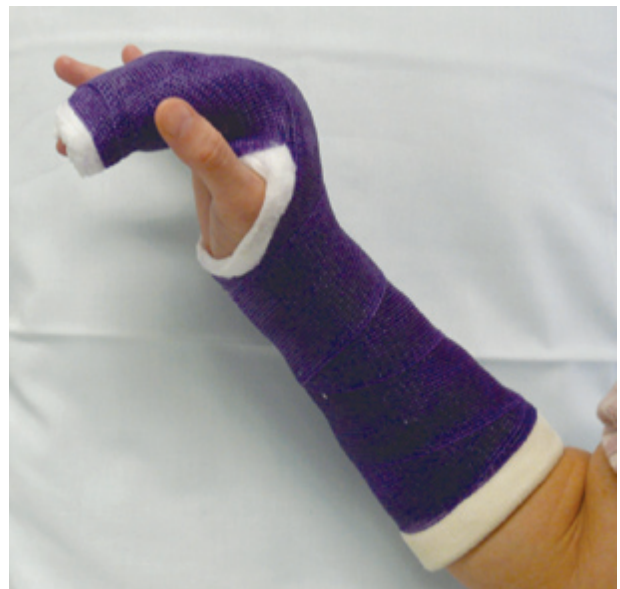

Figure 4. Radial gutter cast.

Splints and Casts

of the base of the first metacarpal; de Quervain tenosynovitis; first carpometacarpal joint arthritis.

Application. The splint covers the radial aspect of the forearm, from the proximal one third of the forearm to just distal to the interphalangeal joint of the thumb, encircling the thumb (*Figure 2*).

Position of Function. The forearm is in the neutral position with the wrist extended to 25 degrees and the thumb in a position of function (i.e., “holding a soda can”).

Pearls and Pitfalls. Immobilization of the thumb with a removable splint after a ligamentous injury is strongly preferred by patients, and the functional results are equal to those of plaster cast immobilization after surgical and nonsurgical treatment.¹²

THUMB SPICA CAST

Common Uses. Suspected or nondisplaced, distal fractures of the scaphoid; nonangulated, nondisplaced, extra-articular fractures of the base of the first metacarpal.

Application. The cast uses the same position of function as described for a thumb spica splint, but requires circumferential application of casting materials (*Figure 5*).

Pearls and Pitfalls. Because these types of fractures are often serious and have a high rate of complications, long-term splinting is not an appropriate definitive treatment. Angulated, displaced, incompletely reduced, or intra-articular fractures of the first metacarpal base should be referred for orthopedic subspecialist evaluation.⁸ Nondisplaced distal fractures of the scaphoid have a greater potential to heal and may be placed in a short arm thumb spica cast and reevaluated out of the cast by radiography in two weeks.^{2,9} Nondisplaced fractures of the middle or proximal one third of the scaphoid are treated with a long arm thumb spica cast initially and require vigilant monitoring for nonunion.²

BUDDY TAPING (DYNAMIC SPLINTING)

Common Uses. Minor finger sprains; stable, nondisplaced, nonangulated shaft fractures of the proximal or middle phalanx.^{7,8}

Application. The injured finger is taped to the adjacent finger for protection and to allow movement (*Online Figure B*).



DORSAL EXTENSION-BLOCK SPLINT

Common Uses. Larger, middle phalangeal volar avulsions with potential for dorsal subluxation; reduced, stable PIP joint dorsal dislocations.

Application. In reduced, volar avulsion fractures, the splint is applied with the PIP joint at 45 degrees of flexion and secured at the proximal finger, allowing flexion at

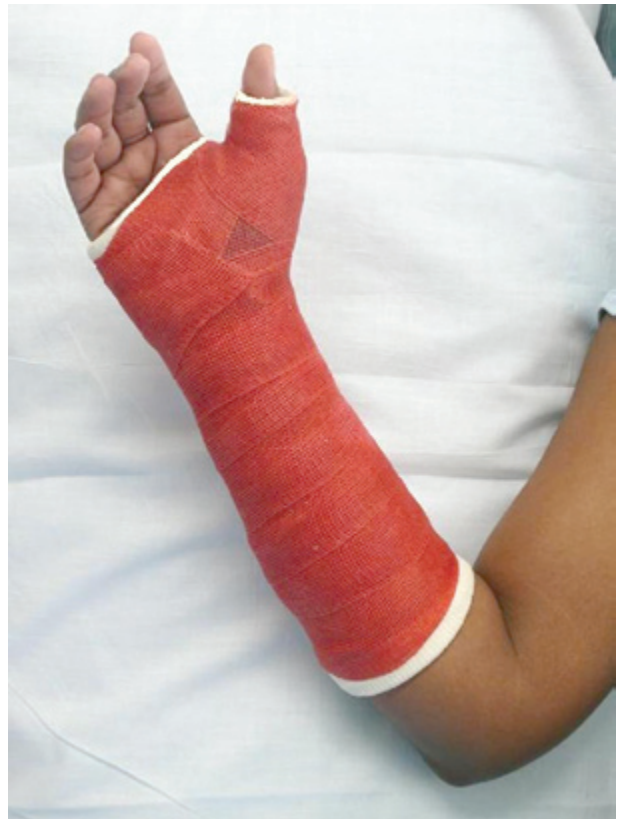

Figure 5. Thumb spica cast.

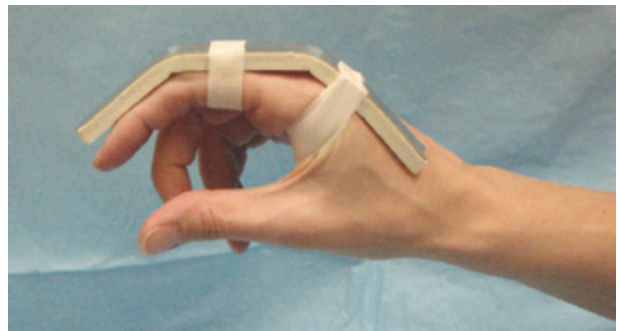


Figure 6. Dorsal extension-block splint.

the PIP joint (*Figure 6*). With weekly lateral radiography, the flexion is decreased 15 degrees until reaching full extension over four weeks. Buddy taping should follow. Treatment of reduced PIP joint dislocations is similar, but requires a starting angle of 20 degrees.

ALUMINUM U-SHAPED SPLINT

Common Uses. Distal phalangeal fractures.

Application. The aluminum splint wraps from the dorsal fingertip around to the volar fingertip and immobilizes only the DIP joint in extension (*Online Figure C*).



MALLET FINGER SPLINTS

Common Uses. Avulsion of the extensor tendon from the base of the distal phalanx (with or without an avulsion fracture).

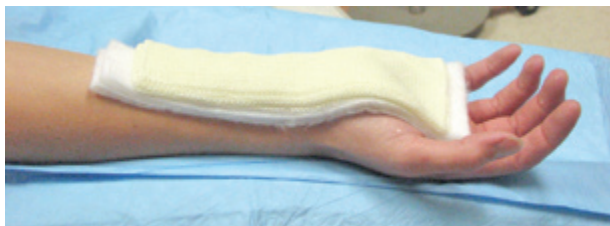

Figure 7. Volar wrist splint.

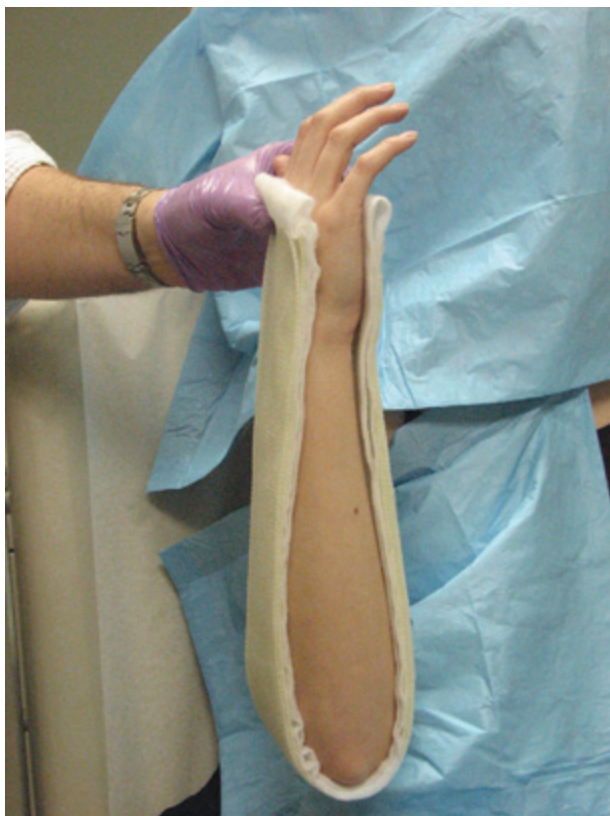

Figure 8. Single sugar-tong splint.

Application. The DIP joint is placed in slight hyperextension with a padded dorsal splint, an unpadded volar splint, or a prefabricated mallet finger splint. Continuous extension in the splint for six to eight weeks is essential, even when changing the splint. Compliance is assessed every two weeks. Night splinting for an additional two to three weeks is recommended.

VOLAR/DORSAL FOREARM SPLINT

Common Uses. Soft tissue injuries of the hand and wrist; temporary immobilization of carpal bone dislocations or fractures (excluding scaphoid and trapezium).

Application. The splint extends from the dorsal or volar mid-forearm to the distal palmar crease (Figure 7).

Position of Function. The wrist is slightly extended.

Pearls and Pitfalls. The splint does not limit forearm pronation and supination, and is generally not recommended for distal radial or ulnar fractures. A recent study, however, demonstrated that compared with cast-

ing for definitive treatment of wrist buckle fractures in children, a removable plaster splint improves physical functioning and satisfaction, with no difference in pain or healing rates.¹³

SHORT ARM CAST

Common Uses. Nondisplaced or minimally displaced fractures of the distal wrist, such as Colles and Smith fractures or greenstick, buckle, and physeal fractures in children; carpal bone fractures other than scaphoid or trapezium.

Application. The cast extends from the proximal one third of the forearm to the distal palmar crease volarly and just proximal to the MCP joints dorsally (Online Figure D).

Position of Function. The wrist is in a neutral position and slightly extended; the MCP joints are free.

Pearls and Pitfalls. These are the same as for a forearm splint.

SINGLE SUGAR-TONG SPLINT

Common Uses. Acute management of distal radial and ulnar fractures.

Application. The splint extends from the proximal palmar crease, along the volar forearm, around the elbow to the dorsum of the MCP joints (Figure 8).

Position of Function. The forearm is neutral and the wrist is slightly extended.

Pearls and Pitfalls. The splint stabilizes the wrist elbow and limits, but does not eliminate, forearm supination and pronation.

LONG ARM POSTERIOR SPLINT

Common Uses. Acute and definitive management of elbow, proximal and mid-shaft forearm, and wrist injuries; acute management of distal radial (nonbuckle) and/or ulnar fractures in children.

Application. The splint extends from the axilla over the posterior surface of the 90-degree flexed elbow, and along the ulna to the proximal palmar crease (Online Figure E).

Pearls and Pitfalls. The posterior splint is not recommended for complex or unstable distal forearm fractures.


LONG ARM CAST

Common Uses. Definitive treatment of injuries initially treated with a posterior splint.

Application. The cast extends from the mid-humerus to the distal palmar crease volarly and just proximal to the MCP joints dorsally.

Position of Function. The elbow is flexed to 90 degrees

Splints and Casts

 with the wrist in a neutral, slightly extended position (Online Figure F).

Pearls and Pitfalls. Adequate padding at the olecranon, ulnar styloid, and antecubital fossa prevents skin breakdown. Physicians should avoid applying the edge of the casting tape over the antecubital fossa, particularly with the initial layer. Long arm casts are used most often in childhood because of the frequency of distal radial, ulnar, and distal humeral fractures.^{2,10,14}

DOUBLE SUGAR-TONG SPLINT

Common Uses. Acute management of elbow and forearm injuries, including Colles fractures.

Application. Physicians should start by placing a single sugar-tong splint, as described above (Figure 8). A second sugar-tong splint is then applied, extending from the deltoid insertion distally around the 90-degree flexed elbow, and proximally to 3 inches short of the axilla (Figure 9).


Pearls and Pitfalls. The splint provides superior pronation and supination control, and is preferable with complex or unstable fractures of the distal forearm and elbow.

Lower Extremity Splints and Casts

POSTERIOR ANKLE SPLINT ("POST-MOLD")

Common Uses. Acute, severe ankle sprain; nondisplaced, isolated malleolar fractures; acute foot fractures and soft tissue injuries.

Application. The splint extends from the plantar surface of the great toe or metatarsal heads along the posterior lower leg and ends 2 inches distal to the fibular head

 to avoid compression of the common peroneal nerve (Online Figure G).

Pearls and Pitfalls. For efficient application, the patient should be placed in a prone position with the knee and ankle flexed to 90 degrees.^{15,16}

STIRRUP SPLINT

Common Uses. Acute ankle injuries; nondisplaced, isolated malleolar fractures.

Application. The splint extends from the lateral mid-calf around the heel, and ends at the medial mid-calf (Online Figure H).¹⁶ The position of function is with the ankle flexed to 90 degrees (neutral).

Pearls and Pitfalls. Stirrup and posterior ankle splints provide comparable ankle immobilization. Although the stirrup splint is adequate for short-term treatment of acute ankle sprains, the evidence favors a functional approach to inversion ankle sprain treatment with the use of a semirigid or soft lace-up brace.¹⁷

A bulky Jones splint is a variation on the stirrup splint

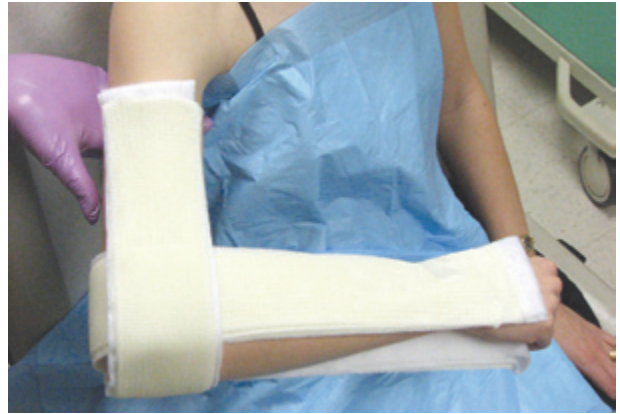


Figure 9. Double sugar-tong splint.

used acutely for more severe ankle injuries. The lower extremity is wrapped with cotton batting and reinforced with a stirrup splint, providing compression and immobilization while allowing for considerable swelling.¹⁶

SHORT LEG CAST

Common Uses. Definitive treatment of injuries to the ankle and foot.

Application. The cast begins at the metatarsal heads and ends 2 inches distal to the fibular head. Additional padding is placed over bony prominences, including  the fibular head and both malleoli (Online Figure I).

Position of Function. The ankle is flexed to 90 degrees (neutral).

Pearls and Pitfalls. Weight-bearing recommendations are determined by the type and stability of the injury and the patient's capacity and discomfort. Short leg walking casts are adequate for nondisplaced fibular and metatarsal fractures.^{2,18} Commercially produced high-top walking boots are acceptable alternatives for injuries at low risk of complications.^{2,19}

TOE PLATE EXTENSIONS

Common Uses. Toe immobilization (comparable to a high-top walking boot or cast shoe); distal metatarsal and phalangeal fractures, particularly of the great toe.

Application. A plate is made by extending the casting material beyond the distal toes, prohibiting plantar flexion and limiting dorsiflexion (Figure 10).^{2,19}

Pearls and Pitfalls. The cast must be molded to the medial longitudinal arch with the ankle at 90 degrees to allow for successful ambulation.

POSTERIOR KNEE SPLINT

Common Uses. Stabilization of acute soft tissue injuries (e.g., quadriceps or patellar tendon rupture, anterior cruciate ligament rupture), patellar fracture or dislocation, and other traumatic lower extremity injuries, particularly when a knee immobilizer is unavailable or unusable because of swelling or the patient's size.

Application. The splint should start just below the

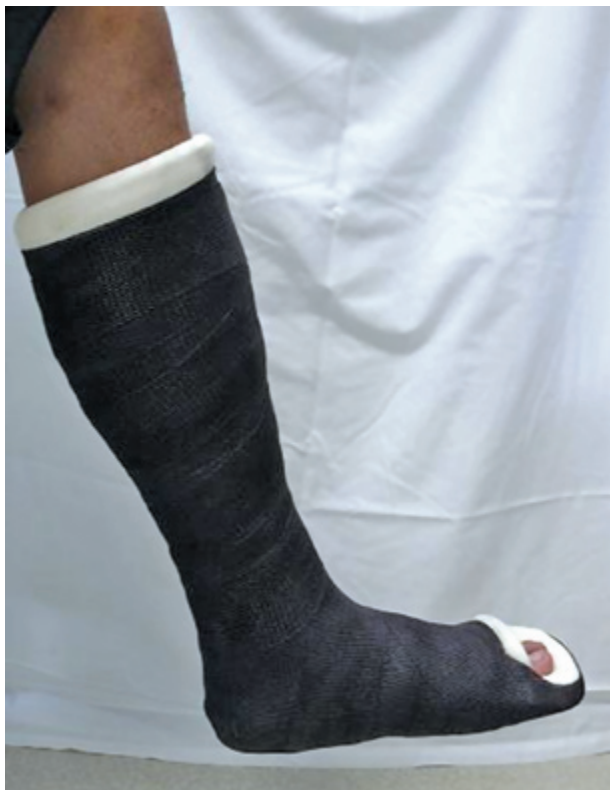

Figure 10. Short leg cast with toe plate extension.



gluteal crease and end just proximal to the malleoli (Online Figure J).

Position of Function. The knee is positioned in slight flexion.

Pearls and Pitfalls. If ankle immobilization is necessary, as with tibial shaft injuries, the splint should extend to include the metatarsals.

The opinions and assertions contained herein are the private views of the authors and are not to be construed as official or as reflecting the views of the U.S. Army or the U.S. Army Medical Service at large.

The Authors

ANNE S. BOYD, MD, FAAFP, is an assistant professor of family medicine at the University of Pittsburgh (Pa.) School of Medicine, and director of the primary care sports medicine fellowship program at the University of Pittsburgh Medical Center, St. Margaret.

HOLLY J. BENJAMIN, MD, FAAP, FACSM, is an associate professor of pediatrics and orthopedic surgery at the University of Chicago (Ill.), and director of the primary care sports medicine program. She serves on the board of directors for the American Medical Society for Sports Medicine, is part of the executive committee for the American Academy of Pediatrics Council on Sports Medicine and Fitness, and is a fellow of the American College of Sports Medicine.

CHAD ASPLUND, MD, is currently a clinical assistant professor of family medicine at The Ohio State University College of Medicine, Columbus. At the time this article was written, he was a clinical faculty member of the Eisenhower Army Medical Center in Fort Gordon, Ga.

Address correspondence to Anne S. Boyd, MD, FAAFP, Lawrenceville Family Health Center, 3937 Butler St., Pittsburgh, PA 15201. Reprints are not available from the authors.

Author disclosure: Nothing to disclose.

REFERENCES

- Chudnofsky CR, Byers S. Splinting techniques. In: Roberts JR, Hedges JR, Chanmugam AS, eds. *Clinical Procedures in Emergency Medicine*. 4th ed. Philadelphia, Pa.: Saunders; 2004:989.
- Eiff MP, Hatch R, Calmbach WL, eds. *Fracture Management for Primary Care*. 2nd ed. Philadelphia, Pa.: Saunders; 2003:1-70.
- Parmelee-Peters K, Eathorne S. The wrist: common injuries and management. *Prim Care*. 2005;32(1):35-70.
- Hong E. Hand injuries in sports medicine. *Prim Care*. 2005;32(1):91-103.
- General principles. In: Simon RR, Sherman SC, Koenigsnecht SJ, eds. *Emergency Orthopedics: The Extremities*. 5th ed. New York, NY: McGraw-Hill; 2007:1-29.
- Boyd AS, Benjamin HJ, Asplund C. Principles of casting and splinting. *Am Fam Physician*. 2009;79(1):16-22.
- Benjamin HJ, Mjannes JM, Hang BT. Getting a grasp on hand injuries in young athletes. *Contemp Pediatr*. 2008;25(3):49-63.
- Lee SG, Jupiter JB. Phalangeal and metacarpal fractures of the hand. *Hand Clin*. 2000;16(3):323-332.
- Slade JF, Magit DP, Geissler WB. Scaphoid fractures in athletes. *Atlas Hand Clin*. 2006;11(1):27-44.
- Overly F, Steele DW. Common pediatric fractures and dislocations. *Clin Pediatr Emerg Med*. 2002;3(2):106.
- Bong MR, Egol KA, Leibman M, Koval KJ. A comparison of immediate postreduction splinting constructs for controlling initial displacement of fractures of the distal radius: a prospective randomized study of long-arm versus short-arm splinting. *J Hand Surg [Am]*. 2006;31(5):766-770.
- Sollerman C, Abrahamsson SO, Lundborg G, Adalbert K. Functional splinting versus plaster cast for ruptures of the ulnar collateral ligament of the thumb. A prospective randomized study of 63 cases. *Acta Orthop Scand*. 1991;62(6):524-526.
- Plint AC, Perry JJ, Correll R, Gaboury I, Lawton L. A randomized, controlled trial of removable splinting versus casting for wrist buckle fractures in children. *Pediatrics*. 2006;117(3):691-697.
- Benjamin HJ, Hang BT. Common acute upper extremity injuries in sports. *Clin Pediatr Emerg Med*. 2007;8(1):15-30.
- Haller PR, Harris CR. The tibia and fibula. In: Ruiz E, Cicero JJ, eds. *Emergency Management of Skeletal Injuries*. St Louis, Mo.: Mosby-Year Book; 1995:499-517.
- Roberts DM, Stallard TC. Emergency department evaluation and treatment of knee and leg injuries. *Emerg Med Clin North Am*. 2000;18(1):67-84.
- Kerkhoffs GM, Struijs PA, Marti RK, Assendelft WJ, Blankevoort L, van Dijk CN. Different functional treatment strategies for acute lateral ankle ligament injuries in adults. *Cochrane Database Syst Rev*. 2002;(3):CD002938.
- Court-Brown CM. Fractures of the tibia and fibula. In: Rockwood CA, Green DP, Buchholz RW, eds. *Rockwood and Green's Fractures in Adults*. 6th ed. Philadelphia, Pa.: Lippincott Williams and Wilkins; 2006:2079-2146.
- LaBella CR. Common acute sports-related lower extremity injuries in children and adolescents. *Clin Pediatr Emerg Med*. 2007;8(1):31-42.