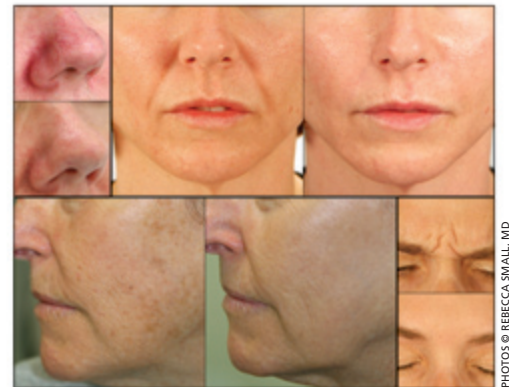

Aesthetic Procedures in Office Practice

REBECCA SMALL, MD, *University of California, San Francisco, School of Medicine, San Francisco, California*

Since the approval of botulinum toxin, dermal fillers, and lasers for cosmetic use, minimally invasive aesthetic procedures have rapidly become the treatments of choice for age-related facial changes. In the past 10 years, aesthetic procedures have increased nearly five-fold. Of the 10.2 million aesthetic treatments performed in 2008, 83 percent were minimally invasive procedures. Botulinum toxin and dermal filler injections, laser hair reduction, chemical peels, laser skin resurfacing, microdermabrasion, and intense pulsed light photorejuvenation were the most commonly performed procedures in 2008. These procedures are effective and associated with minimal discomfort, and they have a low incidence of adverse effects and short recovery times. High patient and physician satisfaction have contributed to their growing popularity and availability in the primary care setting. As patient demand for aesthetic treatments increases, family physicians should be familiar with common minimally invasive aesthetic procedures when advising patients or incorporating aesthetic care into office practice. (*Am Fam Physician*. 2009;80(11):1231-1237, 1238. Copyright © 2009 American Academy of Family Physicians.)



PHOTOS © REBECCA SMALL, MD

► **Patient information:** A handout on cosmetic procedures, written by the author of this article, is provided on page 1238.



The online version of this article includes supplemental content at <http://www.aafp.org/afp>.

The number of aesthetic procedures has increased considerably in the United States over the past 10 years, with nearly a fivefold increase from 1997, according to statistics from the American Society for Aesthetic Plastic Surgery (*Figure 1*).¹ Of the 10.2 million treatments performed in 2008, more than 80 percent were minimally invasive procedures, the most common of which were onabotulinumtoxinA (Botox; formerly known as botulinum toxin type A) and dermal filler injections, laser hair reduction, chemical peels, laser skin resurfacing, microdermabrasion, and intense pulsed light photorejuvenation (*Figure 2*).¹

Minimally invasive procedures have become the primary treatment modalities for addressing mild to moderate age-related facial changes.² In the past, treatment options were limited to surgical interventions, such as facelifts to redrape and lift lax skin, deep ablative laser resurfacing, and dermabrasion to improve texture, wrinkles, and hyperpigmentation.^{3,4} Surgery is still an option for many patients, particularly those with signs of advanced facial aging. However, there has been a trend away from invasive one-time

procedures, which may radically alter appearance and have greater risks, toward minimally invasive nonsurgical procedures, which offer subtle enhancements.⁵ Minimally invasive aesthetic procedures reliably achieve good outcomes, have minimal recovery times⁶ and a low incidence of side effects, and are associated with high patient satisfaction⁷ (*Table 1*⁸⁻¹⁵).

Assessment of aging changes can be approached by evaluation of facial regions. Frown lines, horizontal forehead lines, and crow's feet form in the upper one third of the face. Initially these are dynamic lines, visible during active muscle contraction, but over time they become deeper static lines that can be seen at rest. Prominent nasolabial folds and flattening of malar fat pads appear in the midface. The lower one third of the face exhibits later and more profound changes, with upper lip atrophy, perioral wrinkling, marionette lines, and jowl formation. Skin surface changes are evident in the 30s, with textural roughness and dryness, mottled pigmentation with solar lentigines around the periphery of the face, and telangiectasias around the nasal ala and cheeks¹⁶ (*Online Figure A*).



SORT: KEY RECOMMENDATIONS FOR PRACTICE

Clinical recommendation	Evidence rating	References
OnabotulinumtoxinA (Botox) is safe and effective for reduction of frown lines, crow's feet, and horizontal forehead lines.	A	14, 23, 24
Dermal fillers effectively reduce nasolabial folds.	A	32-34
Laser hair reduction effectively reduces unwanted darkly pigmented hair.	A	36, 38
Laser photorejuvenation effectively reduces benign epidermal pigmented and vascular lesions.	B	45-47
Microdermabrasion reduces benign epidermal pigmented lesions.	B	50, 52
Chemical peels (glycolic and salicylic acid) reduce acne vulgaris.	B	53, 54

A = consistent, good-quality patient-oriented evidence; B = inconsistent or limited-quality patient-oriented evidence; C = consensus, disease-oriented evidence, usual practice, expert opinion, or case series. For information about the SORT evidence rating system, go to <http://www.aafp.org/afpsort.xml>.

Aesthetic Procedure Trends in the United States

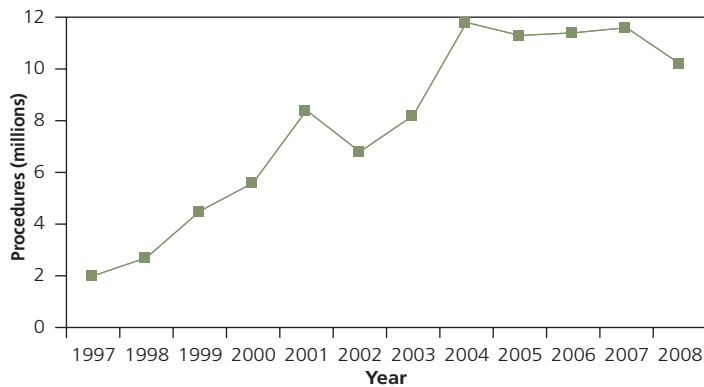


Figure 1. Trends in aesthetic procedures in the United States. In 2008, a total of \$11.8 billion was spent on 10.2 million procedures, 83 percent of which were minimally invasive.

Information from reference 1.

Aesthetic Procedures Performed in 2008

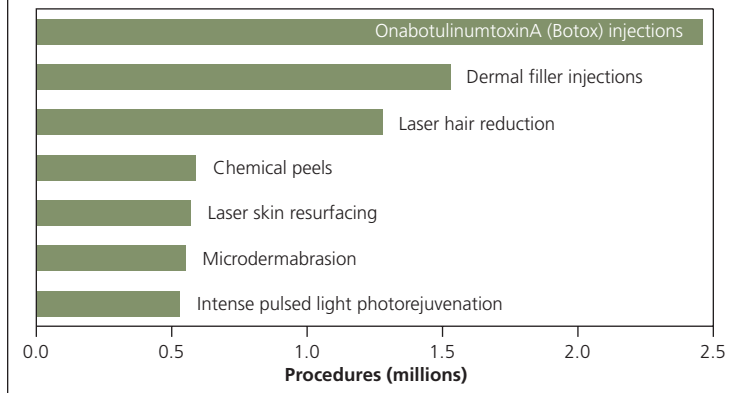


Figure 2. Most common aesthetic procedures performed in 2008.

Information from reference 1.

Minimally invasive procedures can target patients' specific aging complaints by relaxing overactive facial muscles, filling wrinkles, redefining facial contours, reducing unwanted hair, and improving epidermal hyperpigmentation and vascularities.¹⁷ When performed in an ongoing capacity, these procedures can promote and maintain a youthful appearance.⁶

This article is an overview of the most commonly performed minimally invasive aesthetic procedures and the evidence supporting their use, with an emphasis on procedures that family physicians can readily incorporate into office practice.

Botulinum Toxin

Botulinum toxin is a potent neurotoxin protein derived from *Clostridium botulinum*. It exerts its effect at the neuromuscular junction by inhibiting the release of acetylcholine, causing temporary chemical denervation. Injection of small quantities into specific overactive facial muscles causes localized muscle relaxation, with smoothing of the overlying skin and reduction of wrinkles.

Although onabotulinumtoxinA was first noted for its toxic properties, it is now routinely used as a medicine to treat clinical conditions such as blepharospasm, strabismus, cervical dystonia, hyperhidrosis, migraines, and muscle spasticity.¹⁸⁻²⁰ OnabotulinumtoxinA was approved by the U.S. Food and Drug Administration (FDA) for cosmetic use in 2002 as Botox to treat the glabellar complex muscles that form frown lines. It is now the treatment of choice for lines and wrinkles occurring in the upper one third of the face.^{21,22} A similar product, abobotulinumtoxinA (Dysport; formerly known as botulinum toxin type A) was approved by the FDA in 2009 for the treatment of glabellar frown lines as well.

There are many aesthetic indications for onabotulinumtoxinA, but treatment of frown lines²³ and off-label treatment of horizontal forehead lines¹⁴ and crow's feet²⁴ offer the most predictable results, with the greatest effectiveness and fewest adverse effects.^{2,8} Figure 3 shows a woman attempting to contract glabellar complex muscles

Table 1. Minimally Invasive Aesthetic Procedures: Key Points

<i>Procedure</i>	<i>Indication</i>	<i>Treatments required and duration of action</i>	<i>Advantages</i>	<i>Disadvantages</i>
Onabotulinum-toxinA (Botox) injection	Dynamic facial lines and wrinkles in the upper one third of the face	One treatment every three to four months	Short procedure time, dramatic results	Small margin for technical error with injection placement; high patient expectations
Dermal filler injection	Facial wrinkles and folds in the lower two thirds of the face; lip enhancement	One treatment every three to 24 months; duration of action varies with product composition and treatment area (Table 2)	Immediate results	Postprocedure swelling and bruising; injection proficiency and consistency of outcomes require practice
Laser hair reduction	Unwanted hair	Series of six treatments with at least one-month intervals; long-term reduction in hair growth of 50 percent or more	Faster and less painful than other methods of permanent hair reduction, such as electrolysis	Risk of burns, hyperpigmentation, and hypopigmentation*; reduced effectiveness with fine, lighter-colored hair
Laser photo-rejuvenation	Benign epidermal pigmented and vascular lesions	Series of two to five treatments every two to four weeks, based on severity of lesions and device used; results last up to several years	Highly selective for lesions without damaging surrounding skin	Risk of burns, hyperpigmentation, and hypopigmentation*
Micro-dermabrasion	Benign epidermal pigmentation, rough skin texture, acne, fine lines, superficial acne scars	Series of six treatments every two to four weeks with monthly or quarterly maintenance treatments; short-term results	Safe for all skin types; few absolute contraindications	Worsening telangiectasias and erythema possible; minimal change with single treatment
Chemical peels	Benign epidermal pigmentation, rough skin texture, acne, fine lines, superficial acne scars	Series of six treatments per month with monthly to quarterly maintenance treatments; short-term results	Inexpensive	Less control over depth of exfoliation; postprocedure skin peeling; minimal change with single superficial treatment; risk of scarring, hyperpigmentation, and hypopigmentation* with deeper peels

*—Risk of scarring, hyperpigmentation, and hypopigmentation is increased in persons with darker skin.

Information from references 8 through 15.

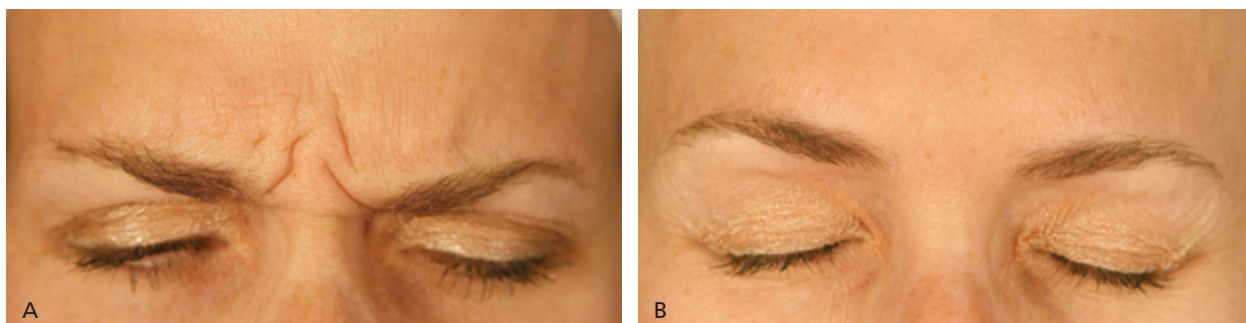

Figure 3. Frown lines. (A) Before treatment with botulinum toxin. (B) One month after treatment (with active frowning).

Aesthetic Procedures

before treatment with botulinum toxin and one month after treatment, with significant reduction in dynamic frown lines.

Dermal Fillers

Dermal fillers are injectable products that temporarily restore soft-tissue volume. They are the treatment of choice for facial lines and contour defects in the lower two thirds of the face.⁹

Dermal fillers vary by composition, duration of action, palpability, ease of administration, complications, and other factors, all of which affect treatment results.^{25,26} Achieving desirable outcomes with dermal fillers depends on the physician's knowledge of filler products and injection skills, as well as an appreciation for aesthetic facial proportions and symmetry. The administration of dermal fillers has a steeper learning curve than that of botulinum toxin and requires practice to consistently achieve desirable results.²⁷

Bovine collagen was one of the first dermal fillers used in the 1980s; however, these products had a duration of action of only three to four months.²⁸ Dermal fillers recently have grown in popularity as new products have been developed, with durations of action from six months to more than one year (Table 2).^{9,25,26}

Hyaluronic acid is one of the most versatile dermal fillers available with regard to depth of placement and treatment areas.²⁹ Hyaluronic acid is a naturally occurring glycosaminoglycan found in the dermal extracellular matrix; it provides structural support, facilitates transport of cellular nutrients and wastes, and adds volume and fullness to the skin through its hydrophilic capacity. After injecting small quantities (1 to 2 mL) into the dermis, facial wrinkles and folds are temporarily reduced and smoothed.³⁰ Some of the most commonly treated areas include the nasolabial folds (Figure 4), lips, oral commissures, and marionette lines^{9,31-34}; however, treatment of the nasolabial fold area is the only FDA-approved indication.

Laser Hair Reduction

Unwanted hair growth is a common aesthetic complaint of men and women¹⁰ (Figure 5). The density of body hair is predetermined at birth; however, most hairs are nonvisible because they are thin, nonpigmented vellus

hairs, or they are dormant. Nonvisible hairs may become visible, pigmented terminal hairs as a result of hormonal changes that occur with age. During menopause, these hairs commonly appear on the chin, upper lip, and anterior neck. In men, new terminal hairs are common on the back and shoulders.³⁵ These changes can be distressing for patients and may affect self-image and self-esteem.

There are numerous laser and other light-based technologies (for the purposes of this article, collectively referred to as lasers) available for hair reduction.^{10,36-38} The basic principle behind these technologies is selective photothermolysis. Energy is absorbed and concentrated in the target by a light-absorbing pigment called a chromophore. The target is heated and damaged, whereas the surrounding skin, which absorbs minimal energy, is unaffected.^{39,40} During hair-reduction treatments, the melanin chromophore in the hair bulb absorbs energy, thereby damaging and impairing the hair growth structures.⁴¹

Table 2. Dermal Fillers

Agent (brand name)	Manufacturer	Active component	Duration of action
Cosmoplast	Allergan Inc.	Collagen	3 to 4 months
Restylane	Medicis Aesthetics	Hyaluronic acid	6 to 9 months
Perlane	Medicis Aesthetics	Hyaluronic acid	6 to 9 months
Juvéderm	Allergan Inc.	Hyaluronic acid	9 to 12 months
Radiesse	Bioform Medical Inc.	Calcium hydroxylapatite	12 to 18 months
Sculptra	Dermik Laboratories	Poly-L-lactic acid	12 to 24 months

Information from references 9, 25, and 26.

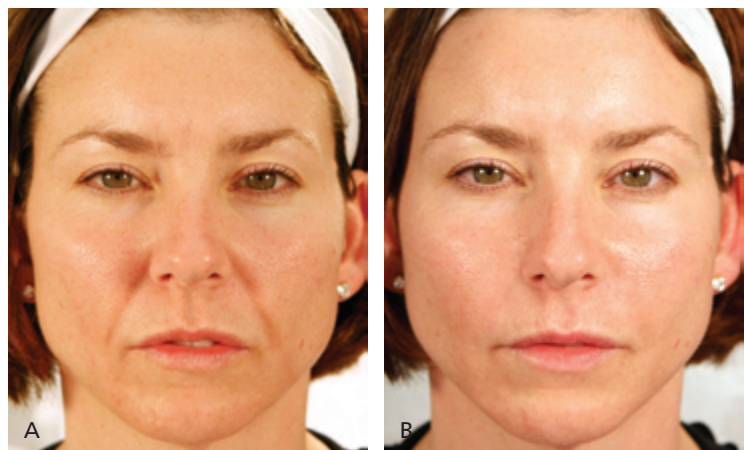

Figure 4. Nasolabial folds. (A) Before treatment with dermal filler. (B) One week after treatment.

Treatment effectiveness is based on patients' skin color and hair characteristics. The best candidates are those with fair skin and coarse, dark hair. Hairs lacking a significant melanin chromophore (e.g., blonde or red hair) are not significantly affected by laser treatments; white and gray hairs do not respond at all.

The safest hair reduction technologies are those with internal cooling mechanisms that provide contact cooling to the skin. These devices maintain a constant temperature of the laser tip throughout treatment. High energies are required to penetrate deeply into the dermis and damage the hair bulb, and cooling mechanisms protect the epidermis from thermal injury and reduce potential complications.⁴²

Laser Photorejuvenation

Many of the skin changes that occur with aging are the result of extrinsic environmental factors, such as cumulative sun exposure, that accelerate the natural aging process.⁴³ These photoaging changes are clinically apparent as benign epidermal pigmented lesions with mottled hyperpigmentation and solar lentigines; benign vascular lesions with telangiectasias, erythema, cherry angiomas, and poikiloderma of Civatte; textural changes with fine lines and laxity; and dysplastic changes with benign and malignant neoplasia⁴⁴ (*Online Figure A*).

Photorejuvenation refers to the laser treatment of benign epidermal pigmented and vascular lesions in photoaged skin^{11,45-47} (*Figures 6 and 7*). Treatments may be performed on virtually any sun-damaged area, and are commonly performed on the face, neck, chest, and hands.⁴⁸ Laser photorejuvenation selectively removes lesions without injuring the surrounding skin by targeting the melanin chromophore in pigmented lesions and the oxyhemoglobin chromophore in vascular lesions.^{39,40} As with laser hair reduction, devices that provide contact skin cooling have the greatest safety profiles.⁴²

Microdermabrasion and Chemical Peels

Microdermabrasion and chemical peels are exfoliation procedures used to superficially

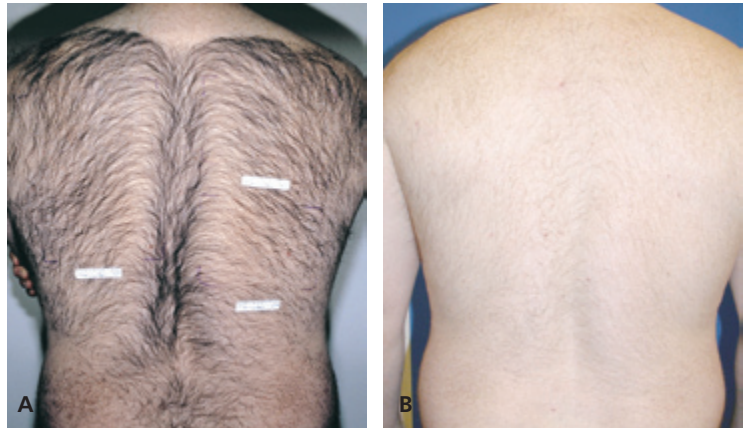

Figure 5. Unwanted hair growth. (A) Before laser hair reduction. (B) After six treatments.

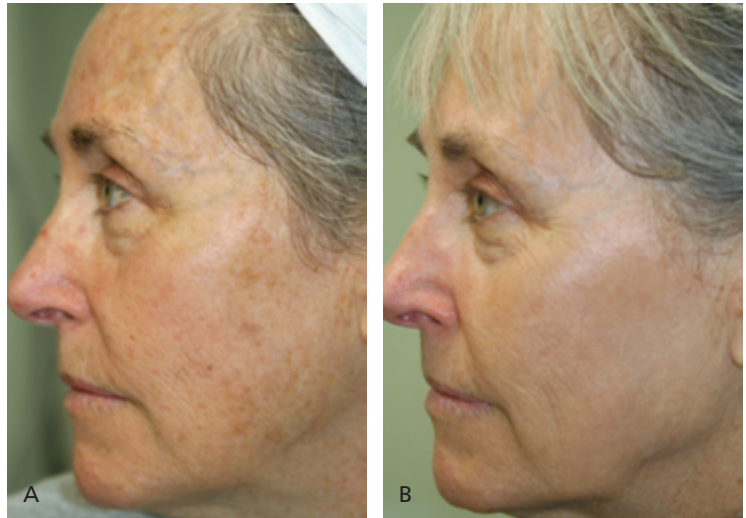

Figure 6. Solar lentigines. (A) Before laser photorejuvenation. (B) After three treatments.

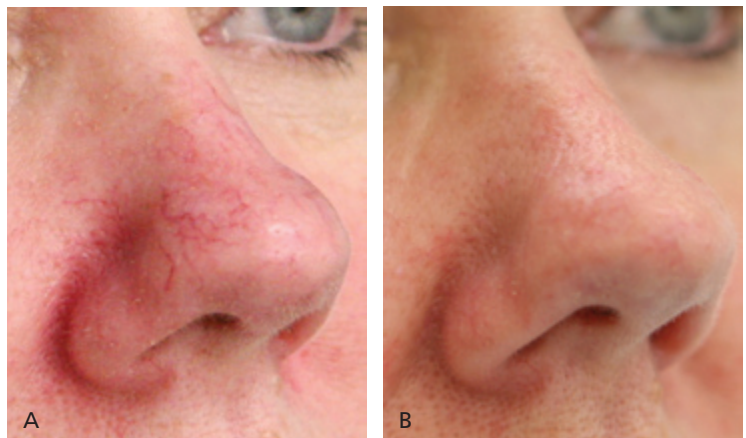


Figure 7. Telangiectasias. (A) Before laser photorejuvenation. (B) After three treatments.

resurface the skin. Skin rejuvenation with exfoliation treatments is based on the principles of wound healing. By wounding and removing superficial skin layers in a controlled manner, cell renewal is stimulated, with regeneration of a healthier epidermis and dermis.⁴⁹ After a series of exfoliation treatments, histologic changes in the skin are evident: a compacted stratum corneum, smoother epidermis, increased dermal thickness with fibroblast production of new collagen and elastin, and increased skin hydration with improved epidermal barrier function.^{50,51} The result is a clinical improvement in benign epidermal pigmented lesions^{50,52} and skin texture, and possible improvements in fine lines, pore size, superficial acne scars, and acne vulgaris.^{12,49,52-56}

Exfoliation procedures can be classified as mechanical or chemical. Microdermabrasion is a method of mechanical exfoliation whereby the stratum corneum is removed using a refined abrasive element, such as diamond-tipped pads or a constant flow of aluminum oxide crystals across the skin. Recent advances in microdermabrasion technology combine exfoliation with simultaneous application of topical products.¹²

Chemical peels are a means of wounding the skin through the application of chemical compounds, such as acids and enzymes. Common agents include alpha hydroxy acids (e.g., glycolic and lactic acids) and beta hydroxy acids (e.g., salicylic acid).^{57,58} The concentration of active ingredients, pH, time, and method of application determine the depth of skin injury and define the procedure as superficial, medium, or deep exfoliation.¹³

Final Comment

The number of aesthetic procedures performed in the United States continues to increase annually because of patient demand and advancements in products and technologies. Minimally invasive aesthetic procedures, including botulinum toxin and dermal filler injections for lines and wrinkles; lasers and intense pulsed light for hair reduction, skin resurfacing, and photorejuvenation; and chemical peels and microdermabrasion for exfoliation are the most common treatments, and have become the basis for facial rejuvenation. They offer patients a means to enhance their appearance in a subtle, natural way, and can help maintain a youthful appearance when performed in an ongoing capacity. From the physician's perspective, these procedures can reliably achieve good outcomes, have a low incidence of side effects, and may be readily incorporated into office practice.

Figures 3 through 7, and Online Figure A © Rebecca Small, MD.

The Author

REBECCA SMALL, MD, is an assistant clinical professor of family and community medicine and director of medical aesthetics training at the University of California, San Francisco, School of Medicine.

Address correspondence to Rebecca Small, MD, University of California, San Francisco, School of Medicine, 995 Potrero Ave., Building 80, Ward 83, San Francisco, CA 94110 (e-mail: rebecca.small@ucsf.edu). Reprints are not available from the author.

Author disclosure: Nothing to disclose.

REFERENCES

1. American Society for Aesthetic Plastic Surgery. Cosmetic Surgery National Data Bank 2008 Statistics. New York, NY: American Society for Aesthetic Plastic Surgery; 2008. <http://www.surgery.org/media/statistics>. Accessed September 17, 2009.
2. Carruthers JD, Glogau RG, Blitzer A, for the Facial Aesthetics Consensus Group Faculty. Advances in facial rejuvenation: botulinum toxin type A, hyaluronic acid dermal fillers, and combination therapies—consensus recommendations. *Plast Reconstr Surg*. 2008;121(5 suppl): 5S-36S.
3. Fitzpatrick RE, Goldman MP, Satur NM, Tope WD. Pulsed carbon dioxide laser resurfacing of photo-aged facial skin. *Arch Dermatol*. 1996; 132(4):395-402.
4. Coleman WP III, Yarborough JM, Mandy SH. Dermabrasion for prophylaxis and treatment of actinic keratoses. *Dermatol Surg*. 1996; 22(1):17-21.
5. Fedok FG. Advances in minimally invasive facial rejuvenation. *Curr Opin Otolaryngol Head Neck Surg*. 2008;16(4):359-368.
6. de Maio M. The minimal approach: an innovation in facial cosmetic procedures. *Aesthetic Plast Surg*. 2004;28(5):295-300.
7. Sommer B, Zschocke I, Bergfeld D, Sattler G, Augustin M. Satisfaction of patients after treatment with botulinum toxin for dynamic facial lines. *Dermatol Surg*. 2003;29(5):456-460.
8. Carruthers J, Fagien S, Matarasso SL, for the Botox Consensus Group. Consensus recommendations on the use of botulinum toxin type A in facial aesthetics. *Plast Reconstr Surg*. 2004;114(6 suppl):1S-22S.
9. Wise JB, Greco T. Injectable treatments for the aging face. *Facial Plast Surg*. 2006;22(2):140-146.
10. Sarkar P, Hirsch RJ. Update on laser hair removal. *Cosmet Dermatol*. 2007; 20(7):440-444.
11. Ross EV, Smirnov M, Pankratov M, Altshuler G. Intense pulsed light and laser treatment of facial telangiectasias and dyspigmentation: some theoretical and practical comparisons. *Dermatol Surg*. 2005;31(9 pt 2): 1188-1198.
12. Grimes PE. Microdermabrasion. *Dermatol Surg*. 2005;31(9 pt 2): 1160-1165.
13. Zakopoulou N, Kontochristopoulou G. Superficial chemical peels. *J Cosmet Dermatol*. 2006;5(3):246-253.
14. Carruthers A, Carruthers J, Cohen J. A prospective, double-blind, randomized, parallel-group, dose-ranging study of botulinum toxin type A in female subjects with horizontal forehead rhytides. *Dermatol Surg*. 2003;29(5):461-467.
15. Ogden S, Griffiths TW. A review of minimally invasive cosmetic procedures. *Br J Dermatol*. 2008;159(5):1036-1050.
16. Zimble MS, Kokoska MS, Thomas JR. Anatomy and pathophysiology of facial aging. *Facial Plast Surg Clin North Am*. 2001;9(2):179-87.
17. Sadick NS. A structural approach to nonablative rejuvenation. *Cosmet Dermatol*. 2002;15(12):39-43.

18. Training guidelines for the use of botulinum toxin for the treatment of neurologic disorders. Report of the Therapeutics and Technology Assessment Subcommittee of the American Academy of Neurology. *Neurology*. 1994;44(12):2401-2403.
19. Naumann M, Lowe NJ. Botulinum toxin type A in treatment of bilateral primary axillary hyperhidrosis: randomised, parallel group, double blind, placebo controlled trial. *BMJ*. 2001;323(7313):596-599.
20. Silberstein S, Mathew N, Saper J, Jenkins S. Botulinum toxin type A as a migraine preventive treatment. For the Botox Migraine Clinical Research Group. *Headache*. 2000;40(6):445-450.
21. Carruthers J, Carruthers A. The use of botulinum toxin type A in the upper face. *Facial Plast Surg Clin North Am*. 2006;14(3):253-260.
22. Maas CS. Botulinum neurotoxins and injectable fillers: minimally invasive management of the aging upper face. *Facial Plast Surg Clin North Am*. 2006;14(3):241-245.
23. Carruthers JD, Lowe NJ, Menter MA, Gibson J, Eadie N, for the Botox Glabellar Lines II Study Group. Double-blind, placebo-controlled study of the safety and efficacy of botulinum toxin type A for patients with glabellar lines. *Plast Reconstr Surg*. 2003;112(4):1089-1098.
24. Lowe NJ, Lask G, Yamauchi P, Moore D. Bilateral, double-blind, randomized comparison of 3 doses of botulinum toxin type A and placebo in patients with crow's feet. *J Am Acad Dermatol*. 2002;47(6):834-840.
25. Johl SS, Burgett RA. Dermal filler agents: a practical review. *Curr Opin Ophthalmol*. 2006;17(5):471-479.
26. Eppley BL, Davand B. Injectable soft-tissue fillers: clinical overview. *Plast Reconstr Surg*. 118(4):98e-106e.
27. Small R. Dermal fillers for facial rejuvenation. In: Mayeaux EJ, ed. *The Essential Guide to Primary Care Procedures*. Philadelphia, Pa.: Wolters Kluwer Health/Lippincott Williams & Wilkins; 2009:214-233.
28. Fagien S, Klein AW. A brief overview and history of temporary fillers: evolution, advantages, and limitations. *Plast Reconstr Surg*. 2007;120(6 suppl):8S-16S.
29. Gold MH. Use of hyaluronic acid fillers for the treatment of the aging face. *Clin Interv Aging*. 2007;2(3):369-376.
30. Born T. Hyaluronic acids. *Clin Plast Surg*. 2006;33(4):525-538.
31. Niamtu J III. Facial aging and regional enhancement with injectable fillers. *Cosmet Dermatol*. 2007;20(5 suppl 2):14-20.
32. Baumann LS, Shamban AT, Lupo MP, et al., for the Juvéderm vs. Zyplast Nasolabial Fold Study Group. Comparison of smooth-gel hyaluronic acid dermal fillers with cross-linked bovine collagen: a multicenter, double-masked, randomized, within-subject study. *Dermatol Surg*. 2007;33(suppl 2):S128-S135.
33. Lupo MP, Smith SR, Thomas JA, Murphy DK, Beddingfield FC III. Effectiveness of Juvéderm Ultra Plus dermal filler in the treatment of severe nasolabial folds. *Plast Reconstr Surg*. 2008;121(1):289-297.
34. Narins RS, Brandt F, Leyden J, Lorenc ZP, Rubin M, Smith S. A randomized, double-blind, multicenter comparison of the efficacy and tolerability of Restylane versus Zyplast for the correction of nasolabial folds. *Dermatol Surg*. 2003;29(6):588-595.
35. Paus R, Cotsarelis G. The biology of hair follicles. *N Engl J Med*. 1999;341(7):491-497.
36. Haedersdal M, Gøtzsche PC. Laser and photoepilation for unwanted hair growth. *Cochrane Database Syst Rev*. 2006;(4):CD004684.
37. Dierickx CC. Hair removal by lasers and intense pulsed light sources. *Semin Cutan Med Surg*. 2000;19(4):267-275.
38. Haedersdal M, Wulf HC. Evidence-based review of hair removal using laser and light sources. *J Eur Acad Dermatol Venereol*. 2006;20(1):9-20.
39. Anderson RR, Parrish JA. Selective photothermolysis: precise microsurgery by selective absorption of pulsed radiation. *Science*. 1983;220(4596):524-527.
40. Lask G, Elman M, Slatkine M, Waldman A, Rozenberg Z. Laser-assisted hair removal by selective photothermolysis. Preliminary results. *Dermatol Surg*. 1997;23(9):737-739.
41. Altshuler GB, Anderson RR, Manstein D, Zenzie HH, Smirnov MZ. Extended theory of selective photothermolysis. *Lasers Surg Med*. 2001;29(5):416-432.
42. Klavuhn KG, Green D. Importance of cutaneous cooling during photothermal epilation: theoretical and practical considerations. *Lasers Surg Med*. 2002;31(2):97-105.
43. Berneburg M, Plettenberg H, Krutmann J. Photoaging of human skin. *Photodermatol Photoimmunol Photomed*. 2000;16(6):239-244.
44. Habif TP. Hair diseases. In: *Clinical Dermatology*. 4th ed. St. Louis, Mo.: Mosby;2003:912-950.
45. Bitter PH. Noninvasive rejuvenation of photodamaged skin using serial, full-face intense pulsed light treatments. *Dermatol Surg*. 2000;26(9):835-842.
46. Weiss RA, Weiss MA, Beasley KL. Rejuvenation of photoaged skin: 5 years results with intense pulsed light of the face, neck, and chest. *Dermatol Surg*. 2002;28(12):1115-1119.
47. Adamic M, Troilius A, Adatto M, Drosner M, Dahmane R. Vascular lasers and IPLS: guidelines for care from the European Society for Laser Dermatology (ESLD). *J Cosmet Laser Ther*. 2007;9(2):113-124.
48. Small R. Laser photo rejuvenation. In: Mayeaux EJ, ed. *The Essential Guide to Primary Care Procedures*. Philadelphia, Pa.: Wolters Kluwer Health/Lippincott Williams & Wilkins; 2009:249-264.
49. Fabbrocini G. Chemical peels. <http://emedicine.medscape.com/article/1125365-overview>. Accessed November 11, 2009.
50. Coimbra M, Rohrich RJ, Chao J, Brown SA. A prospective controlled assessment of microdermabrasion for damaged skin and fine rhytides. *Plast Reconstr Surg*. 2004;113(5):1438-1443.
51. Berardesca E, Distanti F, Vignoli GP, Oresajo C, Green B. Alpha hydroxy-acids modulate stratum corneum barrier function. *Br J Dermatol*. 1997;137(6):934-938.
52. Shim EK, Barnette D, Hughes K, Greenway HT. Microdermabrasion: a clinical and histopathologic study. *Dermatol Surg*. 2001;27(6):524-530.
53. Lee HS, Kim IH. Salicylic acid peels for the treatment of acne vulgaris in Asian patients. *Dermatol Surg*. 2003;29(12):1196-1199.
54. Kessler E, Flanagan K, Chia C, Rogers C, Glaser DA. Comparison of alpha and beta-hydroxy acid chemical peels in the treatment of mild to moderately severe facial acne vulgaris. *Dermatol Surg*. 2008;34(1):45-50.
55. Sadick NS, Finn N. A review of microdermabrasion. *Cosmet Dermatol*. 2005;18(5):351-354.
56. Briden ME. Alpha-hydroxyacid chemical peeling agents: case studies and rationale for safe and effective use. *Cutis*. 2004;73(2 suppl):18-24.
57. Tung RC, Bergfeld WF, Vidimos AT, Remzi BK. Alpha-hydroxy acid-based cosmetic procedures. Guidelines for patient management. *Am J Clin Dermatol*. 2000;1(2):81-88.
58. Kligman D. Technologies for cutaneous exfoliation using salicylic acid. *Dermatol Ther*. 2001;14(3):225-227.