

Delayed Complication from a Tattoo

CHARLES HADDAD, MD; FERN J. WEBB, PhD; and JUDELLA HADDAD-LACLE, MD
University of Florida College of Medicine, Jacksonville, Florida

The editors of *AFP* welcome submissions for Photo Quiz. Guidelines for preparing and submitting a Photo Quiz manuscript can be found in the Authors' Guide at <http://www.aafp.org/afp/photoquizinfo>. To be considered for publication, submissions must meet these guidelines. E-mail submissions to afpphoto@aafp.org. Contributing editor for Photo Quiz is John E. Delzell, Jr., MD, MSPH.

A collection of Photo Quizzes published in *AFP* is available at <http://www.aafp.org/afp/photoquiz>.

A 39-year-old man presented with small nodules that had developed in his tattoos over the previous eight weeks. The nodules were not painful or pruritic. They were present only in the blue portions of the tattoo, but appeared in different tattoos on his arms and upper back (*Figures 1 and 2*). The tattoos were professionally applied about 12 to 13 years prior at the same tattoo parlor.

The patient had diabetes mellitus, hypertension, and gout, which were all well controlled. He was also a smoker. He was taking metformin (Glucophage), glipizide (Glucotrol), allopurinol (Zyloprim), lisinopril (Zestril), and meloxicam (Mobic).

The nodules continued to develop over the next six weeks, after which no significant changes were noted. A biopsy was performed.

Question

Based on the patient's history and physical examination findings, which one of the following is the most likely diagnosis?

- A. Granulomatous reaction.
- B. Keloid.
- C. Pseudolymphomatous reaction.
- D. Pyoderma gangrenosum.

See the following page for discussion.

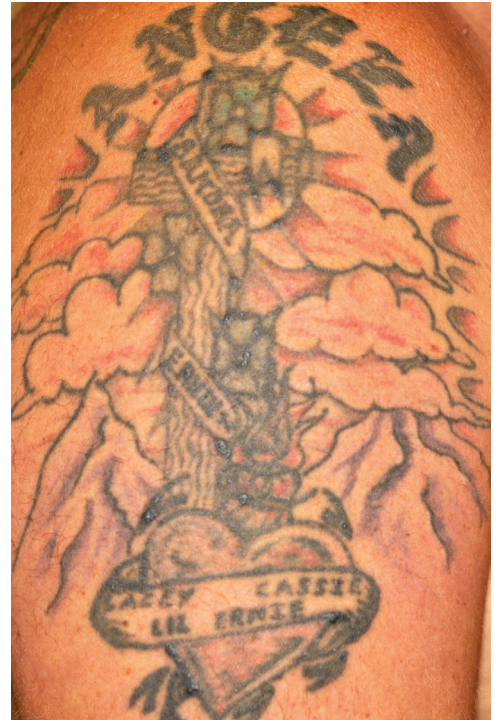


Figure 1.

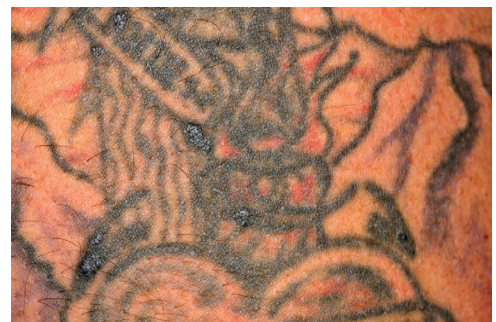

Figure 2.

Discussion

The answer is A: granulomatous reaction. A granulomatous reaction is a giant cell reaction, usually from a foreign body too large to be ingested by polymorphonuclear cells or macrophages.¹ The patient's pathology results confirmed a foreign body granulomatous inflammation from carbonaceous material, possibly tattoo pigment. Granulomatous reactions may be localized hypersensitivity reactions² or local reactions reflecting systemic diseases, such as sarcoidosis.³

Granulomatous reactions from tattoos are thought to be an acquired hypersensitivity reaction to metallic ions in the pigment, and occur in the deeper dermal layers of the skin.⁴ The reaction may appear several months or years after tattoo application. Granulomas have been reported with both artistic and cosmetic tattooing.⁵ Treatment of granulomatous reactions to tattoos has variable success. Topical or intralesional corticosteroid injection or laser ablation may be beneficial; however, these treatments may cause areas of hypopigmentation or scarring within the tattoo. Some reactions may resolve spontaneously.

Keloids are caused by an exuberant healing response, in which fibrous scars extend beyond the borders of the original wound months after trauma or surgery. They occur more often in darkly pigmented skin and in slow-healing wounds, such as burns. Areas more susceptible to keloids include the sternum, upper arms,

earlobes, and cheeks. Keloids occasionally are tender, pruritic, or painful.⁶

Pseudolymphomatous reaction can be a delayed hypersensitivity to tattoo pigment, usually red pigment. Most reactions are characterized by flesh-colored to plum or plum-red indurated nodules and plaques. These can appear similar to cutaneous B-cell lymphoma. The pathologic changes differ from those of a granulomatous reaction by the predominance of lymphoid infiltrate, mainly CD3+ T lymphocytes with pseudolymphomatous reactions and the predominance of polymorphonuclear cells or macrophages with granulomatous reactions.⁷

Pyoderma gangrenosum is an uncommon inflammatory condition of uncertain etiology. It typically begins as a pustule or vesicle that progresses to an ulcer or deep erosion with violaceous overhanging or undermined borders. Pyoderma gangrenosum is characterized by ulcers on the lower extremities, but it may occur anywhere. It is often associated with systemic diseases. It is also associated with ulcerative colitis and diffuse dermal infiltration with neutrophils.⁸

Address correspondence to Charles Haddad, MD, at charles.haddad@jax.ufl.edu. Reprints are not available from the authors.

Author disclosure: No relevant financial affiliations to disclose.

REFERENCES

1. Kazandjieva J, Tsankov N. Tattoos: dermatological complications. *Clin Dermatol*. 2007;25(4):375-382.
2. Jones B, Oh C, Egan CA. Spontaneous resolution of a delayed granulomatous reaction to cosmetic tattoo. *Int J Dermatol*. 2008;47(1):59-60.
3. Papageorgiou PP, Hongcharu W, Chu AC. Systemic sarcoidosis presenting with multiple tattoo granulomas and an extra-tattoo cutaneous granuloma. *J Eur Acad Dermatol Venereol*. 1999;12(1):51-53.
4. Tanzi E. Tattoo reactions. Medscape Reference. <http://emedicine.medscape.com/article/1124433-overview#TattooPigments>. Accessed August 16, 2012.
5. Schwarze H, Giordano-Labadie F, Loche F, Gorguet MB, Bazex J. Delayed-hypersensitivity granulomatous reaction induced by blepharopigmentation with aluminum-silicate. *J Am Acad Dermatol*. 2000;42(5 pt 2):888-891.
6. Juckett G, Hartman-Adams, H. Management of keloids and hypertrophic scars. *Am Fam Physician*. 2009;80(3):253-260.
7. Patrizi A, Raone B, Savoia F, et al. Tattoo-associated pseudolymphomatous reaction and its successful treatment with hydroxychloroquine. *Acta Derm Venereol*. 2009;89(3):327-328.
8. Callen JP, Jackson JM. Pyoderma gangrenosum: an update. *Rheum Dis Clin North Am*. 2007;33(4):787-802. ■

Summary Table

Condition	Characteristics
Granulomatous reaction	Giant cell reaction from a foreign body too large to be ingested by polymorphonuclear cells or macrophages
Keloid	Exuberant healing response occurring months after trauma or surgery; more common in darkly pigmented skin and in slow-healing wounds, such as burns; occasionally tender, pruritic, or painful
Pseudolymphomatous reaction	Pseudolymphoma can be a delayed hypersensitivity to tattoo pigment, usually red pigment
Pyoderma gangrenosum	Typically begins as a pustule or vesicle that progresses to an ulcer or deep erosion with violaceous overhanging or undermined borders; associated with ulcerative colitis and diffuse dermal infiltration with neutrophils