

## Dysphagia in a 58-Year-Old Man

MICHAEL FREELS, MD, and SEAN W. CARLSON, DO, *Mercy Medical Center, Canton, Ohio; Northeastern Ohio Medical University, Rootstown, Ohio*

The editors of *AFP* welcome submissions for Photo Quiz. Guidelines for preparing and submitting a Photo Quiz manuscript can be found in the Authors' Guide at <http://www.aafp.org/afp/photoquizinfo>. To be considered for publication, submissions must meet these guidelines. E-mail submissions to [afpphoto@aafp.org](mailto:afpphoto@aafp.org).

This series is coordinated by John E. Delzell, Jr., MD, MSPH, Assistant Medical Editor.

A collection of Photo Quiz published in *AFP* is available at <http://www.aafp.org/afp/photoquiz>.

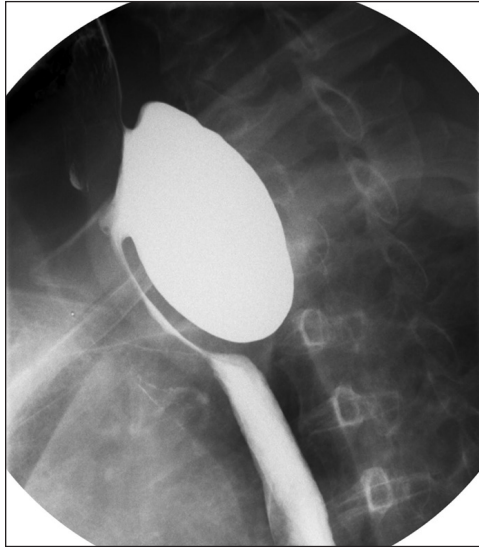


Figure 1.

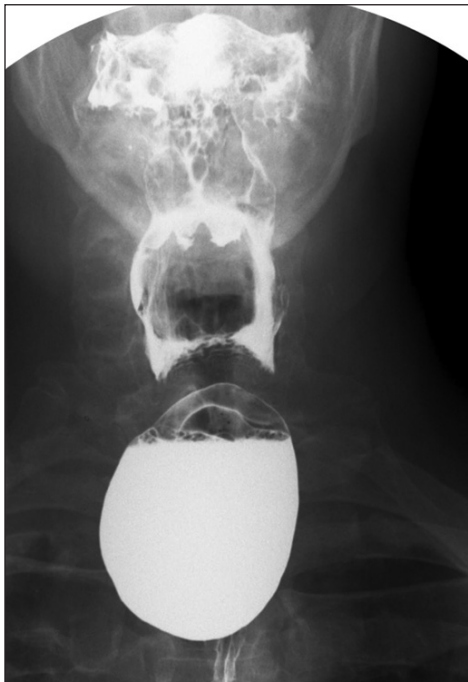


Figure 2.

A 58-year-old man presented to the family medicine clinic with several months of weight loss and difficulty swallowing. He reported that solid foods were “getting stuck” in his throat. He had no relevant medical history, and physical examination findings were normal. Contrast esophagography was performed as an outpatient (*Figures 1 and 2*).

### Question

Based on the patient's history and radiologic findings, which one of the following is the most likely diagnosis?

- A. Esophageal web.
- B. Killian-Jamieson diverticulum.
- C. Meckel diverticulum.
- D. Traction diverticulum.
- E. Zenker diverticulum.

See the following page for discussion.

## Summary Table

Condition	Typical anatomic region	Clinical characteristics
Esophageal web	Upper esophagus	Thin, eccentric mucosal projection into the esophageal lumen; shelf-like filling defect may cause dysphagia, although it is often asymptomatic
Killian-Jamieson diverticulum	Cervical esophagus	Possible dysphagia, cough, or aspiration
Meckel diverticulum	Ileum	May become acutely inflamed or result in gastrointestinal bleeding or bowel obstruction
Traction diverticulum	Midthoracic esophagus	Possible dysphagia and regurgitation
Zenker diverticulum	Hypopharynx	Possible dysphagia, cough, aspiration, halitosis, regurgitation

## Discussion

The answer is E: Zenker diverticulum. A Zenker diverticulum is an uncommon posterior herniation of hypopharyngeal mucosa. It occurs through an area of weakness between the inferior pharyngeal constrictor and the cricopharyngeus muscles known as the Killian triangle. The pathogenesis is unclear, but the condition is thought to result from incomplete opening of the upper esophageal sphincter, which causes increased hypopharyngeal pressures and resultant protrusion. Dysphagia, cough, halitosis, and regurgitation of food are common.<sup>1,2</sup> Complications may include aspiration pneumonia and, less commonly, bleeding and fistula formation.<sup>1</sup> For symptomatic, large diverticula, open or endoscopic surgical repair may be required.

Esophageal webs are typically thin, eccentric mucosal projections into the esophageal lumen. They usually arise from the anterior wall of the proximal esophagus.<sup>3</sup> Esophageal webs may be idiopathic, congenital, or related to inflammatory processes. They are often asymptomatic, but patients may present with dysphagia.<sup>3,4</sup> An esophagogram classically reveals an anterior shelf-like filling defect.

A Killian-Jamieson diverticulum occurs in the upper cervical esophagus and protrudes from the anterolateral aspect of the esophagus through an area inferior to the cricopharyngeus muscle. It may cause dysphagia, cough, or aspiration.<sup>5,6</sup>

A Meckel diverticulum is a congenital, usually ileal outpouching from persistence of the omphalomesenteric duct and is not associated with the esophagus. It is commonly described using the rule of twos, in which the diverticulum is typically located 2 ft from the ileocecal valve, presents before two years of age, and is found in 2% of the population. A Meckel diverticulum may become acutely inflamed or result in gastrointestinal bleeding or bowel obstruction.<sup>7</sup>

A traction diverticulum is an outpouching of the esophagus that develops because of pulling from adjacent inflammatory changes. It is more common in the mid-thoracic esophagus because of adjacent mediastinal, hilar, or pulmonary pathology. Dysphagia and regurgitation may occur.<sup>8</sup>

Address correspondence to Michael Freels, MD, at [mfreels1@hotmail.com](mailto:mfreels1@hotmail.com). Reprints are not available from the authors.

Author disclosure: No relevant financial affiliations.

## REFERENCES

1. Ferreira LE, Simmons DT, Baron TH. Zenker's diverticula: pathophysiology, clinical presentation, and flexible endoscopic management. *Dis Esophagus*. 2008;21(1):1-8.
2. Grant PD, Morgan DE, Scholz FJ, Canon CL. Pharyngeal dysphagia: what the radiologist needs to know. *Curr Probl Diagn Radiol*. 2009;38(1):17-32.
3. Tobin RW. Esophageal rings, webs, and diverticula. *J Clin Gastroenterol*. 1998;27(4):285-295.
4. Spieker MR. Evaluating dysphagia. *Am Fam Physician*. 2000;61(12):3639-3648.
5. Tang SJ, Tang L, Chen E, Myers LL. Flexible endoscopic Killian-Jamieson diverticulotomy and literature review (with video). *Gastrointest Endosc*. 2008;68(4):790-793.
6. Ekberg O, Nylander G. Lateral diverticula from the pharyngo-esophageal junction area. *Radiology*. 1983;146(1):117-122.
7. Uppal K, Tubbs RS, Matusz P, Shaffer K, Loukas M. Meckel's diverticulum: a review. *Clin Anat*. 2011;24(4):416-422.
8. do Nascimento FA, Lemme EM, Costa MM. Esophageal diverticula: pathogenesis, clinical aspects, and natural history. *Dysphagia*. 2006;21(3):198-205. ■