

Photo Quiz

Digital Clues

Rob Danoff, DO, MS, and Julia Todd, DO, Jefferson Health Northeast
Family Medicine/Emergency Medicine Residency, Philadelphia, Pennsylvania

A 90-year-old man presented with increasing fatigue over the previous two to three months. His daughter reported that he was fatigued with simple activities of daily living. The patient had not been seen by a physician for approximately 10 years. He reported a decreased appetite and mild dyspnea on exertion, but no chest pain. He had no symptoms of depressed mood. He had a history of poststreptococcal glomerulonephritis when he was a teenager, but no other medical conditions.

On physical examination, his blood pressure and pulse while sitting were normal. He had pallor and skin turgor appropriate for an older person. Cardiac and pulmonary examination findings were normal. He had no cyanosis in the extremities; however, his fingernails were deformed (*Figures 1 and 2*).

Question

Based on the patient's history and physical examination findings, which one of the following is the most likely diagnosis?

- A. Iron deficiency anemia.
- B. Onychomycosis.
- C. Psoriasis.
- D. Squamous cell carcinoma.

See the following page for discussion.

FIGURE 1

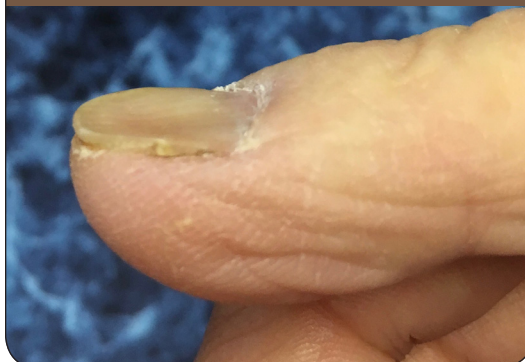
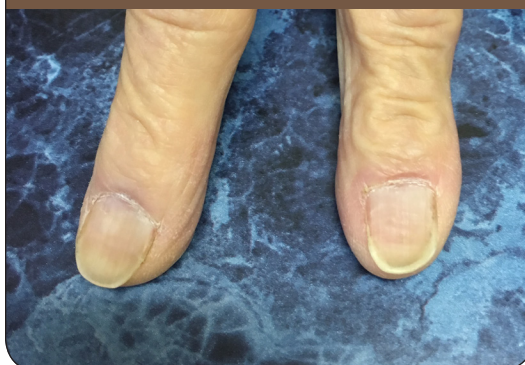

FIGURE 2



The editors of *AFP* welcome submissions for Photo Quiz. Guidelines for preparing and submitting a Photo Quiz manuscript can be found in the Authors' Guide at <http://www.aafp.org/afp/photoquizinfo>. To be considered for publication, submissions must meet these guidelines. E-mail submissions to afpphoto@aaafp.org

This series is coordinated by John E. Delzell Jr., MD, MSPH, Associate Medical Editor.

A collection of Photo Quiz published in *AFP* is available at <http://www.aafp.org/afp/photoquiz>.

Previously published Photo Quizzes are now featured in a mobile app. Get more information at <http://www.aafp.org/afp/apps>.

Discussion

The answer is A: iron deficiency anemia. Spoon-shaped nails (koilonychia) are often indicative of a systemic illness. Iron deficiency anemia is the most common cause of isolated koilonychia.¹ Patients with iron overload, as in hemochromatosis, may also develop koilonychia.² A complete blood count and ferritin level should be ordered for patients with koilonychia to rule out iron abnormalities. Koilonychia can also be caused by occupational exposure to solvents or by chronic trauma,³ and it is a normal physiologic finding in infants.² Other common signs and symptoms of iron deficiency anemia include weakness and fatigue, pale skin, chest pain or palpitations, dizziness, and pica (craving for ice or dirt).

Onychomycosis, a fungal nail infection, commonly affects the toenails but can also affect the fingernails. Fungi from the skin invades the nail bed, creating the appearance of onycholysis, hyperkeratosis, and yellow streaks.² Proximal subungual onychomycosis, which appears as fungal hyphae in the deeper layers of the nail plate, is more common in patients who are immunocompromised and requires systemic treatment.

Most patients with psoriasis (80% to 90%) will develop onychodystrophy as a result of psoriatic involvement of the nail bed or nail matrix.^{2,4} The classic presentation is a pitted appearance of the fingernails. Patients may also have subungual hyperkeratosis and onycholysis.⁴

Squamous cell carcinoma, a proliferating, erythematous mass, originates from the surrounding tissues and may be mistaken for onychomycosis.² There should be a high index of suspicion for squamous cell carcinoma when treatment for onychomycosis is ineffective. A biopsy confirms the diagnosis.

SUMMARY TABLE

Iron deficiency anemia	Spoon-shaped nail (koilonychia); other common signs and symptoms include weakness and fatigue, pale skin, chest pain or palpitations, dizziness, and pica (craving for ice or dirt)
Onychomycosis	Fungi from the skin invades the nail bed, creating the appearance of onycholysis, hyperkeratosis, and yellow streaks
Psoriasis	Irregular, deep, and randomly distributed pits of the fingernails
Squamous cell carcinoma	Proliferating, erythematous mass

Address correspondence to Rob Danoff, DO, MS, at rdanoff@ariahealth.org. Reprints are not available from the authors.

Author disclosure: No relevant financial affiliations.

References

1. Killip S, Bennett JM, Chambers MD. Iron deficiency anemia [published correction appears in *Am Fam Physician*. 2008;78(8):914]. *Am Fam Physician*. 2007;75(5):671-678.
2. Tully AS, Traves KP, Studdiford JS. Evaluation of nail abnormalities. *Am Fam Physician*. 2012;85(8):779-787.
3. Onychomycosis. In: Usatine RP. *The Color Atlas of Family Medicine*. New York, NY: McGraw-Hill; 2013:829-833.
4. Armstrong AW. Nail psoriasis. Updated August 15, 2017. UpToDate. <https://www.uptodate.com/contents/nail-psoriasis> [subscription required]. Accessed May 16, 2017. ■