

Telemedicine Management of Musculoskeletal Issues

Nicole T. Yedlinsky, MD, University of Kansas Medical Center, Kansas City, Kansas

Rebecca L. Peebles, DO, Ehrling Bergquist Family Medicine Residency Program, Offutt Air Force Base, Nebraska; Uniformed Services University of the Health Sciences, Bethesda, Maryland

Telemedicine can provide patients with cost-effective, quality care. The coronavirus disease 2019 pandemic has highlighted the need for alternative methods of delivering health care. Family physicians can benefit from using a standardized approach to evaluate and diagnose musculoskeletal issues via telemedicine visits. Previsit planning establishes appropriate use of telemedicine and ensures that the patient and physician have functional telehealth equipment. Specific instructions to patients regarding ideal setting, camera angles, body positioning, and attire enhance virtual visits. Physicians can obtain a thorough history and perform a structured musculoskeletal examination via telemedicine. The use of common household items allows physicians to replicate in-person clinical examination maneuvers. Home care instructions and online rehabilitation resources are available for initial management. Patients should be scheduled for an in-person visit when the diagnosis or management plan is in question. Patients with a possible deformity or neurovascular compromise should be referred for urgent evaluation. Follow-up can be done virtually if the patient's condition is improving as expected. If the condition is worsening or not improving, the patient should have an in-office assessment, with consideration for referral to formal physical therapy or specialty services when appropriate. (*Am Fam Physician*. 2021;103:online. Copyright © 2021 American Academy of Family Physicians.)



Illustration by Jennifer Fairman

Published online January 12, 2021.

Telemedicine has rapidly become a valuable tool during the coronavirus disease 2019 (COVID-19) pandemic.¹ Given that musculoskeletal issues are a common reason for primary care visits,^{2,3} a standardized examination to evaluate these issues via telemedicine is useful. Video-assisted orthopedic consultation for selected patients is cost-effective and does not result in serious adverse events.^{4,5}

This article discusses telemedicine methods and techniques, including visit preparation,

history collection, virtual physical examination, and initial treatment options.

Virtual Visit Preparation

Before the visit, initial preparation includes confirming that the patient has functional audiovisual resources and providing instructions on ideal setting, camera angles, body positioning, and attire.⁶ The physician should review any previous imaging studies beforehand. Multiple telehealth platforms are compliant with the U.S. Health Insurance Portability and Accountability Act (HIPAA).⁷ A guide for preparing a medical practice for virtual visits was published previously in *FPM*.⁸

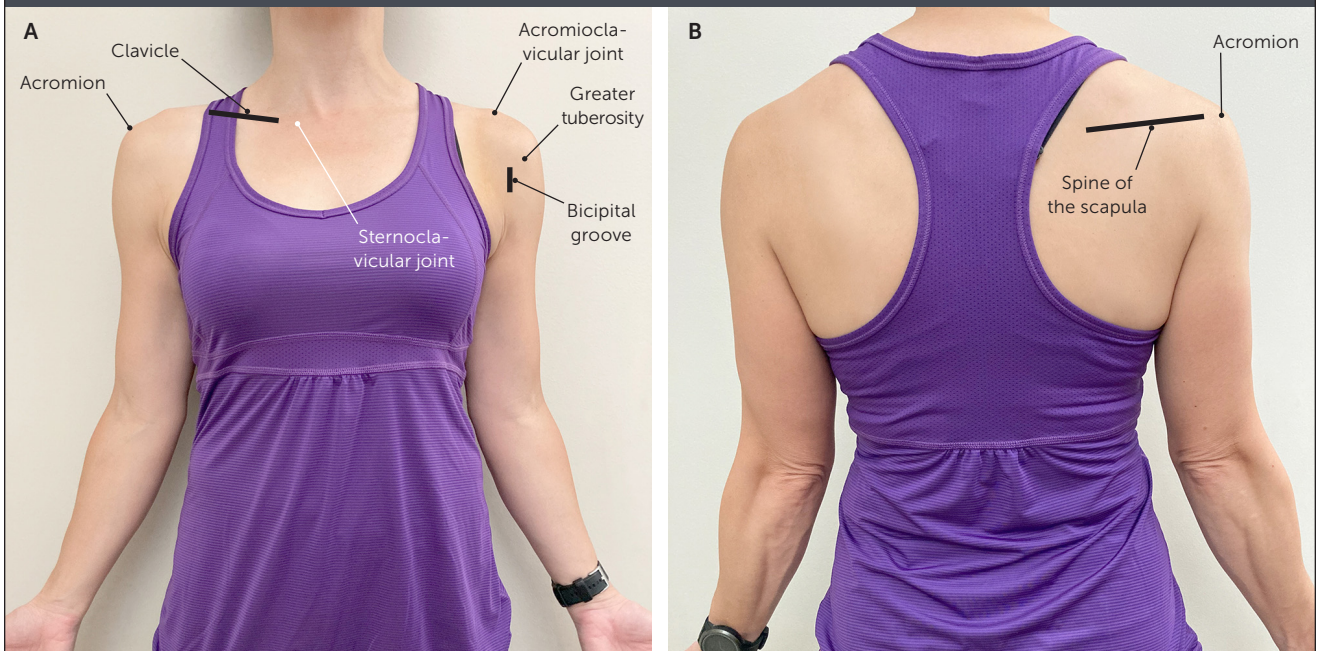Virtual Musculoskeletal Evaluation

Patients should be asked about the timing and characteristics of symptom onset, associated

CME credit for this article will be available when it is published in print.

Author disclosure: No relevant financial affiliations.

FIGURE 1



Shoulder palpation positioning. (A) Anterior view. (B) Posterior view.

trauma, location of pain, presence of swelling, subsequent course, and current status. Functional impact on activities of daily living, employment, and recreational activities should be established. Physicians should ask about previous injuries and surgeries, as well as previous management and response.

The virtual physical examination should include inspection, palpation, range of motion, strength, neurovascular assessment, and special tests.^{9,10} Although certain maneuvers are difficult to perform virtually, modifications can provide useful information. It may be helpful for the patient to mirror the physician's motions.

SHOULDER

For shoulder problems, the physician should ask if the patient's primary concern is pain, weakness, or decreased range of motion. Pain in the absence of a recent traumatic event often indicates shoulder impingement or calcific tendinopathy.¹¹ Pain with cross-arm adduction can indicate acromioclavicular pathology.^{9,11,12} Weakness suggests complete rotator cuff tear or nerve pathology. Decreased range of motion raises suspicion for

adhesive capsulitis or severe osteoarthritis.^{9,13,14} Patients should also be asked about distal neurovascular symptoms of the upper extremity, such as weakness or paresthesia.

The virtual physical examination begins with inspection. The patient should wear a tank top or sports bra according to individual comfort. The patient should be asked to face the camera and then slowly rotate their body 360 degrees so that the physician can observe the shoulder joint in all planes. The physician should look for asymmetry, deformity, abnormal posture, overlying skin changes, atrophy, erythema, and ecchymosis.

The physician should ask the patient to point to the area of maximal tenderness. The patient should be directed to use the contralateral hand to palpate the sternoclavicular joint, clavicle, acromioclavicular joint, acromion, and spine of the scapula, as range of motion allows. Patients can also locate and palpate the bicipital groove and greater tuberosity of the humerus with direction from the physician (*Figure 1*).

Shoulder abduction, forward flexion, extension, external rotation, and internal rotation

TABLE 1

Telemedicine Assessment of Upper Extremity Range of Motion

Plane of range of motion	Patient body positioning*	Normal range of motion (degrees) ¹¹
Shoulder		
Abduction	Away from the camera	180
Extension	90 degrees to the side	45 to 60
Flexion	90 degrees to the side for measurement, away from the camera for scapular stability	180
Internal rotation	Away from the camera for Apley scratch test	Able to reach vertebral height of T4-T8
	90 degrees to the side, elbow abducted to 90 degrees	90
External rotation	90 degrees to the side, elbow at the side	90
	90 degrees to the side, elbow abducted to 90 degrees	90
Elbow		
Flexion	Facing the camera, arm abducted to 90 degrees	135 to 150
Extension	Same as flexion	-10 to 0
Supination	Facing the camera, elbow resting on table with arm to the side and elbow flexed to 90 degrees	75 to 90
Pronation	Same as supination	75 to 90
Wrist		
Dorsiflexion	90 degrees to the side	70
Palmar flexion	Same as dorsiflexion	80 to 90
Radial deviation	Facing the camera	20 to 30
Ulnar deviation	Facing the camera	50

*—Relative to the camera.

Information from reference 11.

active range of motion (*Table 1*¹¹) should be assessed. Alterations of scapular motion during abduction and flexion indicate scapular dyskinesia or weakness of the scapular stabilizing muscles.

Strength testing can be performed by asking the patient to move their shoulder against gravity or by using common household items (*Table 2*). *Table 3* summarizes suggested rotator cuff strength tests.^{9,11,15} Neurovascular assessment can be completed by having the patient perform a wall push-up so that the physician can look for scapular winging. Special tests of the shoulder, such as Speed test to check for proximal biceps tendinopathy and O'Brien test to detect labral pathology, can be performed using household items as resistance.

ELBOW

Virtual examination of the elbow begins with inspection of the affected side and comparison with the unaffected side, looking for erythema, deformity, swelling, ecchymosis, and overlying skin changes. The biceps and triceps should be checked for deformity to evaluate for tendon rupture. The patient should palpate over the lateral epicondyle, medial epicondyle, and olecranon to check for tenderness (*Figure 2*). Range of motion assessment is reviewed in *Table 1*.¹¹ Strength of elbow flexion and extension can be assessed using gravity or common household items (*Table 2*). Pain that localizes to the lateral epicondyle with wrist extension and supination while holding a weighted object is suggestive of lateral epicondylitis. Similarly, pain that localizes to the medial epicondyle with wrist flexion and pronation while holding a weighted object is suggestive of medial epicondylitis.

HAND AND WRIST

The hand and wrist should be inspected for an obvious deformity, swelling,

TABLE 2

Common Household Items That Can Be Used in Telemedicine Strength Testing

Item	Approximate weight
Roll of nickels, cup of sugar, or three C cell batteries	0.5 lb (0.23 kg)
Can of soup, block of butter, or 16-oz bottle of water	1 lb (0.45 kg)
Quart of milk or 1-L bottle of soda	2 lb (0.91 kg)
Bag of sugar or 2-L bottle of soda	5 lb (2.27 kg)
Gallon of milk or large bag of potatoes	9 lb (4.08 kg)

ecchymosis, overlying skin and nail changes, and atrophy compared with the contralateral side. The patient should be asked to point to the area of maximal tenderness and/or paresthesia. If the patient reports a recent traumatic injury, tenderness when palpating the anatomical snuff-box warrants further evaluation for scaphoid fracture¹⁶ (Figure 3).

Wrist range of motion should be assessed as outlined in Table 1.¹¹ Hand range of motion is best assessed by asking the patient to make a fist, then extend the hand. If there is a concern about a flexor or extensor tendon rupture after traumatic injury, the patient should be asked to isolate movement at the proximal interphalangeal and distal interphalangeal joints. Special tests in

TABLE 3

Telemedicine Assessment of Rotator Cuff Strength

Supraspinatus

Patient lifts an object in the plane of scaption (90 degrees of abduction and approximately 30 degrees of forward flexion)

Patient fully abducts the arm and then slowly reverses the motion in the same arc. Test is positive for rotator cuff tear if arm drops suddenly or patient has severe pain (drop-arm sign)

Infraspinatus and teres minor

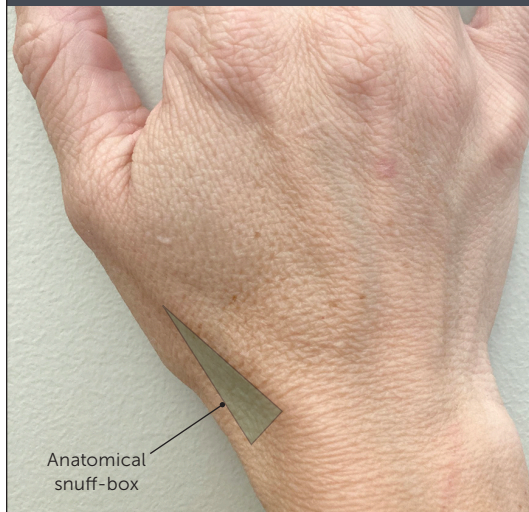Patient lies on unaffected side and externally rotates against gravity or with an object

Subscapularis

With the patient facing to the side and the arm internally rotated behind the back, the patient lifts the hand away from the back against gravity (lift-off test)

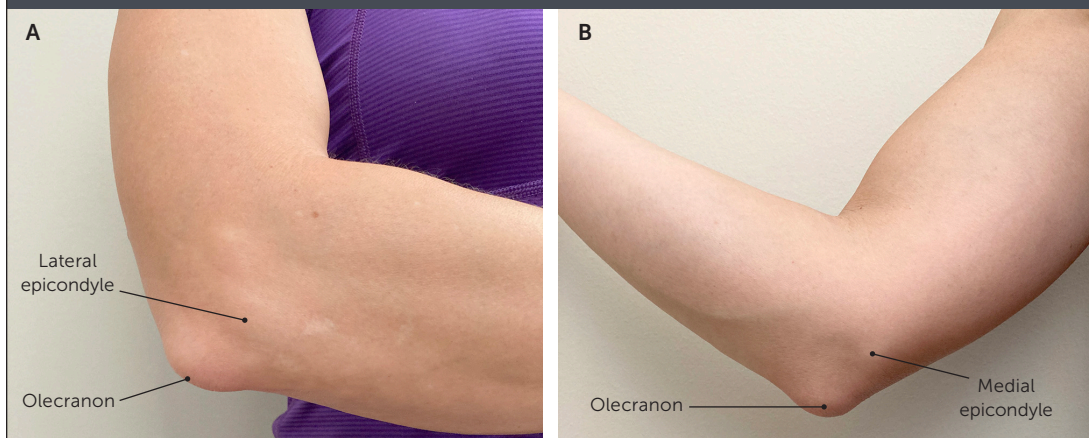
Information from references 9, 11, and 15.

FIGURE 3



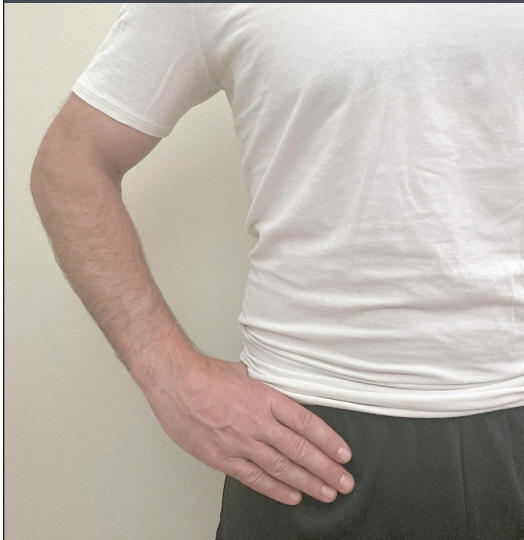Anatomical snuff-box. Tenderness with palpation after a traumatic injury warrants further evaluation for scaphoid fracture.

FIGURE 2



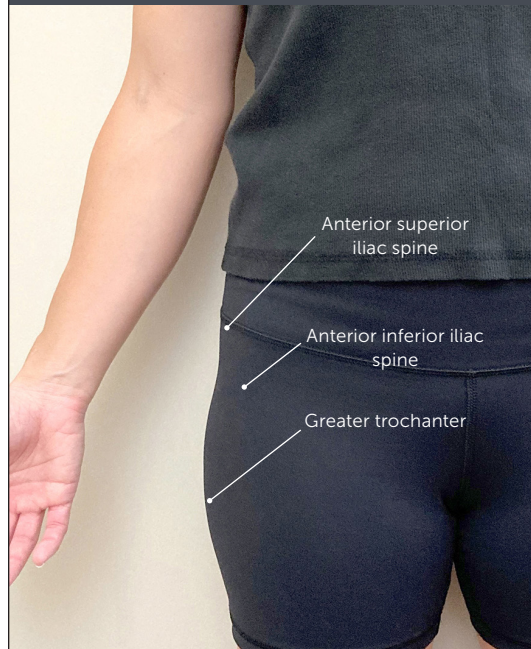
Elbow palpation positioning. (A) Lateral view. (B) Medial view.

FIGURE 4



C sign. If the patient localizes pain by cupping the anterolateral hip with the thumb and forefinger in the shape of a "C," intra-articular pathology should be suspected.

FIGURE 5



Hip palpation positioning.

the evaluation of the hand and wrist are summarized in *eTable A*.

HIP AND PELVIS

Virtual examination of the hip and pelvis begins with inspecting the patient standing, facing the camera, with feet shoulder width apart. The physician should ask the patient to place both hands, palms down, on the top of the iliac crests as the physician looks for symmetry in hand height and anterior/posterior alignment. Asymmetry of the iliac crest can indicate leg length discrepancy or pelvic rotation. Next, the patient should point to the most painful area. C sign around the hip (*Figure 4*) should raise suspicion for intra-articular pathology.¹⁷ The physician can then guide the patient to palpate the anterior superior iliac spine, anterior inferior iliac spine, and greater trochanter to check for tenderness (*Figure 5*).

Assessment of hip range of motion is summarized in *Table 4*.^{10,11} Strength can be assessed with heel walking (L4), toe walking (L5/S1), hip extension (L5/S1), hip abduction while the patient is lying on their side (gluteus medius, L5), and the patient standing unassisted.⁶ The patient can be

asked to point along any areas of paresthesia. Special tests in the assessment of the hip are summarized in *eTable B*.

KNEE

The knee examination should begin with observation of gait. Next, the knee is inspected for swelling, deformity, erythema, ecchymosis, and obvious muscle atrophy compared with the contralateral side. The patient should be asked to point with one finger to the location of maximal pain. The patient can next be guided to palpate the quadriceps and patellar tendons, patella, iliotibial band insertion, tibial tubercle, pes anserinus, and joint lines (*Figure 6*). If the patient reports recent trauma, the Ottawa Knee Rule (<https://www.mdcalc.com/ottawa-knee-rule>) can be used to determine whether imaging is necessary to evaluate for a fracture.^{10,11,18,19}

Assessment of knee range of motion is detailed in *Table 4*.^{10,11} Strength should be assessed with the patient seated and the knee in active flexion and extension. Inability to actively extend the knee should raise suspicion for patellar or quadriceps tendon injury and requires imaging.⁶ Special

TABLE 4

Telemedicine Assessment of Lower Extremity Range of Motion

Plane of range of motion	Patient body positioning*	Normal range of motion (degrees) ^{10,11}
Hip		
Flexion	90 degrees to the side, standing or supine position; knee is pulled to the chest	120
Extension	90 degrees to the side, standing or prone position, with extended straight leg	10 to 20
Internal rotation	Facing the camera, seated with knee bent to 90 degrees and leg rotated at the hip (not the knee)	40
External rotation	Same as internal rotation	45
Knee		
Flexion	Affected side facing the camera, seated	130 to 135
Extension	Affected side facing the camera (allows for demonstration of hyperextension if present), standing	-10 to 0
Ankle		
Dorsiflexion	Affected side facing the camera, seated with knees bent and feet not touching the floor	20
Plantar flexion	Same as dorsiflexion	45
Inversion	Facing the camera, seated with knees bent and feet not touching the floor	30
Eversion	Same as inversion	20

*—Relative to the camera.

Information from references 10 and 11.

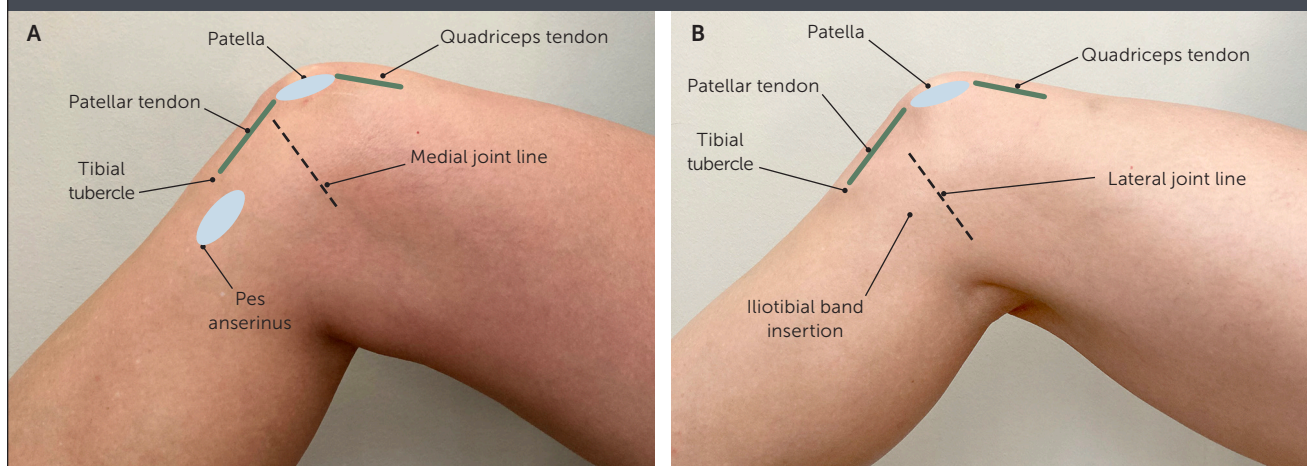
tests in the assessment of the knee are summarized in *eTable C*

ANKLE AND FOOT

Virtual examination of the ankle and foot should be performed with the patient barefoot and wearing shorts and the patient's camera positioned low enough for adequate visualization. The physician should inspect the ankle and foot for edema, gross deformity, ecchymosis, erythema, and muscle atrophy in comparison with the contralateral side. The patient should be directed to stand, facing away from the camera, with feet shoulder width apart. The physician counts the number of toes that are visible lateral to each ankle. If more than 2 1/2 toes are seen, hyperpronation or out-toeing should be considered. The physician should assess for pes cavus or pes planus and observe hindfoot and knee alignment, standing and walking, to check for valgus or varus deformity.

Next, the patient should sit facing the camera and point to the area of maximal pain. In patients with a traumatic injury such as an ankle inversion, the Ottawa Ankle Rule

FIGURE 6



Knee palpation positioning. (A) Medial view. (B) Lateral view.

SORT: KEY RECOMMENDATIONS FOR PRACTICE

Clinical recommendation	Evidence rating	Comments
Video-assisted orthopedic consultation for selected patients is cost-effective. ⁴	B	Economic evaluation based on randomized controlled trial comparing video-assisted remote consultation with standard care
Video-assisted orthopedic consultation for selected patients does not result in serious adverse events. ⁵	B	Randomized controlled trial comparing video-assisted remote consultation at a regional medical center with standard consultation at an orthopedic outpatient clinic
The management of musculoskeletal conditions via telerehabilitation is effective in improving physical function, disability, and pain. ²⁴	B	Systematic review

A = consistent, good-quality patient-oriented evidence; B = inconsistent or limited-quality patient-oriented evidence; C = consensus, disease-oriented evidence, usual practice, expert opinion, or case series. For information about the SORT evidence rating system, go to <https://www.aafp.org/afpsort>.

(<https://www.mdcalc.com/ottawa-ankle-rule>) can be used to determine whether imaging is needed to evaluate for a foot or ankle fracture.^{11,20-22} The proximal fibula should also be palpated after a traumatic ankle injury to evaluate for an associated Maisonneuve fracture.

Assessment of ankle range of motion is detailed in Table 4.^{10,11} Strength can be evaluated against gravity or against resistance with a towel or exercise band. With good lighting and appropriate camera positioning, capillary refill distal to the injury can be assessed. The physician can guide the patient to check for gross sensation to light touch along dermatomal distributions. In a traumatic injury, the squeeze test may be performed by having the patient apply circumferential pressure to the largest part of the calf; pain along the distal tibiofibular interosseous membrane suggests a high ankle sprain.²²

Previous articles in *American Family Physician* discuss the evaluation of the shoulder,^{9,12} elbow,²³ hand/wrist,¹⁶ hip,¹⁷ knee,¹⁰ and foot/ankle²² in more detail.

Management

Findings from the virtual history and physical examination often suggest a likely diagnosis. However, physicians should have a low threshold for proceeding with further evaluation if the diagnosis or initial management is unclear. If there is concern for deformity or neurovascular compromise, the patient should be referred for

further evaluation in the office or emergency department. Further evaluation may include an in-person examination and/or imaging studies.

An initial telemedicine visit may avoid unnecessary imaging studies. If the patient will be seen in person, obtaining appropriate imaging in advance can streamline the evaluation. If imaging is available at the time of a virtual encounter, screen-sharing capabilities can allow the physician to review results with the patient.

Home care instructions and online rehabilitation resources are available for initial management and are especially helpful when clinical resources are limited, the patient has transportation challenges, or exposure to the clinical setting could be detrimental to the patient.²⁴ The management of musculoskeletal conditions via telerehabilitation is effective in improving physical function, disability, and pain.²⁴

Follow-up may be performed virtually if the patient's condition is improving as expected. If the condition is worsening or not improving, the patient should have an in-office assessment, with consideration for referral to formal physical therapy or specialty services when appropriate.

Data Sources: PubMed and the Cochrane database were searched using the key terms telemedicine, telehealth, virtual, orthopedic, musculoskeletal, and rehabilitation. Essential Evidence Plus was also searched. Search dates: May to November 2020.

The contents of this article are solely the views of the authors and do not necessarily represent the official

views of the Uniformed Services University of the Health Sciences, the U.S. military at large, the U.S. Department of Defense, or the U.S. government.

The Authors

NICOLE T. YEDLINSKY, MD, CAQSM, FAAFP, RMSK, is a faculty member with the University of Kansas Family Medicine Residency and Primary Care Sports Medicine Fellowship programs, and is an assistant professor in the Department of Family Medicine and Community Health at the University of Kansas Medical Center, Kansas City.

REBECCA L. PEEBLES, DO, CAQSM, FAAFP, is a faculty member at the Ehrling Bergquist Family Medicine Residency program, Offutt Air Force Base, Neb., and is an assistant professor in the Department of Family Medicine at the Uniformed Services University of the Health Sciences, Bethesda, Md.

Address correspondence to Nicole T. Yedlinsky, MD, CAQSM, FAAFP, RMSK, University of Kansas School of Medicine, 3901 Rainbow Blvd., Mailstop 4010, Kansas City, KS 66160 (email: nyedlinsky@kumc.edu). Reprints are not available from the authors.

References

1. U.S. Centers for Medicare and Medicaid Services. Telehealth services. March 2020. Accessed July 7, 2020. <https://www.cms.gov/Outreach-and-Education/Medicare-Learning-Network-MLN/MLNProducts/Downloads/TelehealthSrvcsfctst.pdf>
2. Schappert SM, Burt CW. Ambulatory care visits to physician offices, hospital outpatient departments, and emergency departments: United States, 2001-02. *Vital Health Stat* 13. 2006;(159):1-66.
3. U.S. Department of Health and Human Services. National ambulatory medical care survey: 2016 national summary tables. Accessed August 25, 2020. https://www.cdc.gov/nchs/data/nhamcs/web_tables/2016_ed_web_tables.pdf
4. Buvik A, Bugge E, Knutsen G, et al. Quality of care for remote orthopaedic consultations using telemedicine: a randomised controlled trial. *BMC Health Serv Res*. 2016; 16(1):483.
5. Buvik A, Bergmo TS, Bugge E, et al. Cost-effectiveness of telemedicine in remote orthopedic consultations: randomized controlled trial. *J Med Internet Res*. 2019;21(2): e11330.
6. Tanaka MJ, Oh LS, Martin SD, et al. Telemedicine in the era of COVID-19: the virtual orthopaedic examination [published correction appears in *J Bone Joint Surg Am*. 2020; 102(20):e121]. *J Bone Joint Surg Am*. 2020;102(12):e57.
7. U.S. Department of Health and Human Services. Notification of enforcement discretion for telehealth remote communications during the COVID-19 nationwide public health emergency. Accessed July 7, 2020. <https://www.hhs.gov/hipaa/for-professionals/special-topics/emergency-preparedness/notification-enforcement-discretion-telehealth/index.html>
8. Magoon V. Operationalizing virtual visits during a public health emergency. *Fam Pract Manag*. 2020;27(3):5-12. Accessed August 26, 2020. <https://www.aafp.org/fpm/2020/0500/p5.html>
9. Burbank KM, Stevenson JH, Czarnecki GR, et al. Chronic shoulder pain: part I. Evaluation and diagnosis. *Am Fam Physician*. 2008;77(4):453-460. Accessed August 25, 2020. <https://www.aafp.org/afp/2008/0215/p453.html>
10. Bunt CW, Jonas CE, Chang JG. Knee pain in adults and adolescents: the initial evaluation. *Am Fam Physician*. 2018;98(9):576-585. Accessed August 25, 2020. <https://www.aafp.org/afp/2018/1101/p576.html>
11. McGee SR. Examination of the musculoskeletal system. In: *Evidence-Based Physical Diagnosis*. 3rd ed. Elsevier Saunders; 2012:477-510.
12. Monica J, Vredenburg Z, Korsh J, et al. Acute shoulder injuries in adults. *Am Fam Physician*. 2016;94(2):119-127. Accessed August 26, 2020. <https://www.aafp.org/afp/2016/0715/p119.html>
13. Ramirez J. Adhesive capsulitis: diagnosis and management. *Am Fam Physician*. 2019;99(5):297-300. Accessed August 25, 2020. <https://www.aafp.org/afp/2019/0301/p297.html>
14. Clarnette RG, Miniaci A. Clinical exam of the shoulder. *Med Sci Sports Exerc*. 1998;30(4 suppl):S1-S6.
15. Codman EA. *The Shoulder; Rupture of the Supraspinatus Tendon and Other Lesions in or About the Subacromial Bursa*. Todd Company; 1934.
16. Forman TA, Forman SK, Rose NE. A clinical approach to diagnosing wrist pain. *Am Fam Physician*. 2005;72(9):1753-1758. Accessed August 26, 2020. <https://www.aafp.org/afp/2005/1101/p1753.html>
17. Wilson JJ, Furukawa M. Evaluation of the patient with hip pain. *Am Fam Physician*. 2014;89(1):27-34. Accessed August 25, 2020. <https://www.aafp.org/afp/2014/0101/p27.html>
18. Stiell IG, Greenberg GH, Wells GA, et al. Derivation of a decision rule for the use of radiography in acute knee injuries. *Ann Emerg Med*. 1995;26(4):405-413.
19. Yao K, Haque T. The Ottawa Knee Rules - a useful clinical decision tool. *Aust Fam Physician*. 2012;41(4):223-224.
20. Stiell IG, Greenberg GH, McKnight RD, et al. A study to develop clinical decision rules for the use of radiography in acute ankle injuries. *Ann Emerg Med*. 1992;21(4): 384-390.
21. Barelds I, Krijnen WP, van de Leur JP, et al. Diagnostic accuracy of clinical decision rules to exclude fractures in acute ankle injuries: systematic review and meta-analysis. *J Emerg Med*. 2017;53(3):353-368.
22. Tiemstra JD. Update on acute ankle sprains. *Am Fam Physician*. 2012;85(12):1170-1176. Accessed August 25, 2020. <https://www.aafp.org/afp/2012/0615/p1170.html>
23. Kane SF, Lynch JH, Taylor JC. Evaluation of elbow pain in adults. *Am Fam Physician*. 2014;89(8):649-657. Accessed August 25, 2020. <https://www.aafp.org/afp/2014/0415/p649.html>
24. Cottrell MA, Galea OA, O'Leary SP, et al. Real-time telerehabilitation for the treatment of musculoskeletal conditions is effective and comparable to standard practice: a systematic review and meta-analysis. *Clin Rehabil*. 2017;31(5):625-638.

eTABLE A

Special Tests for Evaluating the Hand and Wrist

Test	Technique	Condition
Finkelstein test	Patient grasps a weighted object and tilts wrist down (ulnar deviation) against gravity	Pain with this maneuver suggests de Quervain tenosynovitis
Froment sign	Patient grasps a piece of paper between thumb and index finger on affected side and attempts to pull it out with opposite hand	Difficulty holding paper suggests ulnar nerve injury
Phalen test	With arms raised to the level of shoulders, patient brings dorsum of hands together in midline, holding in forced flexion for 30 to 60 seconds	Burning, numbness, or tingling in the median nerve distribution suggests carpal tunnel syndrome
Press test	Seated patient pushes their body weight up off a chair using affected wrist ^{A1}	Focal ulnar wrist pain with this maneuver suggests triangular fibrocartilage complex injuries
Reverse Phalen test	With arms raised to the level of shoulders, patient brings palms together in midline, holding in forced flexion for 30 to 60 seconds	Carpal tunnel syndrome (same as Phalen test)

Note: A video of shoulder assessments is available at <https://www.youtube.com/watch?v=ZpynPil6mdg>.

A1. Lester B, Halbrecht J, Levy IM, et al. "Press test" for office diagnosis of triangular fibrocartilage complex tears of the wrist. *Ann Plast Surg.* 1995;35(1):41-45.

eTABLE B

Special Tests for Evaluating the Hip

Test	Technique	Condition
FABER (Patrick) test	While the patient is lying on their back, the hip is flexed, abducted to the side, and externally rotated into a "figure of four" position	Sacroiliac joint or intra-articular pathology (depending on localization of pain)
FADIR test	While the patient is lying on their back, the hip is flexed, adducted toward midline, and internally rotated	Pain suggests intra-articular pathology
Trendelenburg test	Patient stands facing away from camera and balances on one foot for 30 seconds	Inability to maintain pelvis stability parallel to the ground suggests pelvic instability (stance leg)

FABER = flexion, abduction, external rotation; FADIR = flexion, adduction, internal rotation.

Information from:

Friedrich Trendelenburg (1844-1924). *Trendelenburg's position.* *JAMA.* 1969;207(6):1143-1144.

Wilson JJ, Furukawa M. *Evaluation of the patient with hip pain.* *Am Fam Physician.* 2014;89(1):27-34. Accessed August 25, 2020. <https://www.aafp.org/afp/2014/0101/p27.html>

eTABLE C

Special Tests for Evaluating the Knee

Test	Technique	Condition
J sign	While seated and facing the camera, patient actively flexes and extends the knee as physician observes patellar motion	Patellar tracking
Single leg squat	While standing and facing the camera, patient squats on one leg for three or four repetitions as physician observes knee alignment and balance	Pelvic instability (stance leg)
Thessaly test	While facing the camera, patient stands on one leg; the supporting leg is flexed 20 to 30 degrees and trunk is rotated back and forth	Pain with a mechanical click or catching sensation suggests meniscal pathology

Note: Patients may use a sturdy chair or wall for support during the single leg squat and Thessaly test.

Information from:

Bunt CW, Jonas CE, Chang JG. Knee pain in adults and adolescents: the initial evaluation. *Am Fam Physician*. 2018;98(9):576-585. Accessed August 25, 2020. <https://www.aafp.org/afp/2018/1101/p576.html>

Karachalios T, Hantes M, Zibis AH, et al. Diagnostic accuracy of a new clinical test (the Thessaly test) for early detection of meniscal tears. *J Bone Joint Surg Am*. 2005;87(5):955-962.