

Rash in an Eight-Year-Old Boy

A.S. PILLAI, DO, FAAFP, and D. MEDINA, MD, *The Methodist Hospital Family Medicine Residency Program, Houston, Texas*

The editors of *AFP* welcome submissions for Photo Quiz. Guidelines for preparing and submitting a Photo Quiz manuscript can be found in the Authors' Guide at <http://www.aafp.org/afp/photoquizinfo>. To be considered for publication, submissions must meet these guidelines. E-mail submissions to afpphoto@aafp.org. Contributing editor for Photo Quiz is John E. Delzell, Jr., MD, MSPH.

A collection of Photo Quizzes published in *AFP* is available at <http://www.aafp.org/afp/photoquiz>.

An eight-year-old boy presented with blisters on his lower lip and tongue that had appeared two days earlier. One day after the blisters appeared, a nonpruritic, bilateral rash developed on his palms and soles. The patient recently had swum at a community pool, after which he reported fatigue. He had no fever, chills, nausea, vomiting, rhinorrhea, cough, or history of recent travel. His activity levels and appetite were normal. The patient's immunizations were up to date, and he had no significant medical history.

Physical examination demonstrated erythematous, 2-mm ulcers in the oral mucosa of his lower lip (*Figure 1*), an erythematous pharynx, and tender vesicles on the hard palate and tongue. The skin examination revealed erythematous papules and vesicles with a surrounding rim of erythema on both of the palms and soles (*Figures 2 and 3*).

Question

Based on the patient's history and physical examination findings, which one of the following is the most likely diagnosis?

- ☐ A. Aphthous stomatitis.
- ☐ B. Hand-foot-and-mouth disease.
- ☐ C. Herpangina.
- ☐ D. Herpes labialis.
- ☐ E. Rocky Mountain spotted fever.

See the following page for discussion.

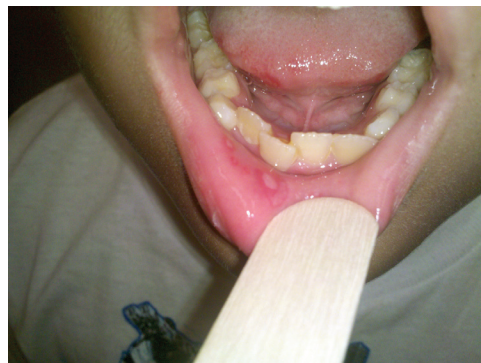


Figure 1.

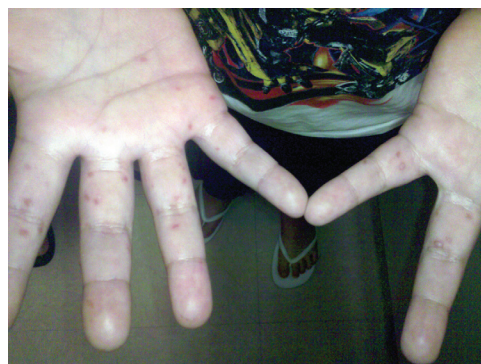

Figure 2.

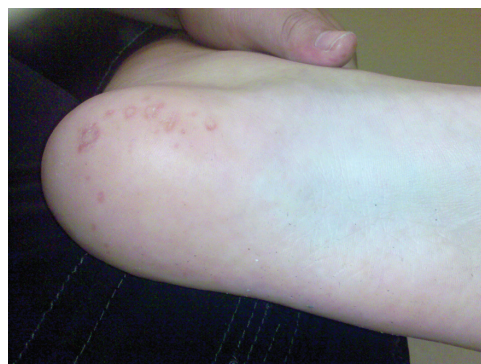

Figure 3.

Discussion

The answer is B: hand-foot-and-mouth disease. This disease is caused by enteroviruses, most commonly coxsackievirus A5, A7, A9, A10, A16, B2, or B5, and enterovirus 71.¹ Hand-foot-and-mouth disease usually occurs in children younger than 10 years. The infection is spread by direct contact with infected nasal discharge, saliva, blister fluid, or stool. The virus can remain in the body for several weeks after symptoms resolve.

The typical clinical presentation is painful oral lesions, and a nonpruritic rash on the palms and soles or the groin and buttocks. Oral lesions begin as erythematous macules that evolve into tender, 3- to 5-mm vesicles on an erythematous base.^{1,2} A one-day prodrome of low-grade fever (in some patients), anorexia, malaise, abdominal pain, and upper respiratory tract symptoms may also be present.

Aphthous stomatitis is a common oral ailment that typically appears in childhood, disappearing around 30 years of age.¹ The disease leads to painful oral ulcers, which are typically covered by a white to yellow pseudomembrane measuring 2 to 8 mm in diameter. They usually affect nonkeratinized mucosa, such as the labial and buccal mucosa and the floor of the mouth or the ventral surface of the tongue, and are surrounded by an erythematous halo.^{3,4}

Herpangina is an acute viral illness appearing between three and 10 years of age, although infection can occur in adults and neonates. The incidence is highest in one- to seven-year-olds.⁵ It is caused by enteroviruses (coxsackievirus A16 or B, and enterovirus 71).⁵ Herpangina is most common during the fall and summer. Clinical manifestations can vary but may include high fever and odynophagia, which leads to decreased appetite. The vesicles, which may persist for up to one week, are approximately 1 to 4 mm in diameter and tender. They are surrounded by erythematous rings and appear on the soft palate, uvula, and anterior tonsillar pillars.²

Herpes labialis is caused by herpes simplex virus type 1. Primary infection usually occurs through nonsexual contact during childhood, usually appearing two to 20 days after contact with an infected person.² Transmission involves mucous membranes and open or abraded skin. Symptoms may include a prodrome of fever, followed by tender oral lesions and lymphadenopathy. The classic oral lesions appear as a cluster of small vesicles on an erythematous base at the vermilion border of the lip. The lesions spontaneously heal within two weeks.^{2,4}

Summary Table

Condition	Characteristics
Aphthous stomatitis	Painful oral ulcers measuring approximately 2 to 8 mm in diameter; affects nonkeratinized mucosa
Hand-foot-and-mouth disease	Viral prodrome and rash on the palms and soles or the groin and buttocks; painful oral lesions begin as erythematous macules and evolve into tender, 3- to 5-mm vesicles on an erythematous base
Herpangina	Tender, 1- to 4-mm vesicles surrounded by an erythematous ring on the soft palate, uvula, and anterior tonsillar pillars; may be associated with high fever and odynophagia, which leads to decreased appetite
Herpes labialis	Cluster of tender vesicles on an erythematous base appearing at the vermilion border of the lip
Rocky Mountain spotted fever	Small, blanching, pink macules measuring 1 to 4 mm in diameter initially on the ankles and wrists; spreads centrally to the palms and soles, sparing the face, and evolves into macules, papules, and petechiae; ultimately coalesces into large ecchymoses and ulcerations; usually associated with fever, myalgias, arthralgias, fatigue, and travel to endemic regions

Rocky Mountain spotted fever is a tick-borne disease caused by *Rickettsia rickettsii*. It is typically characterized by fever, myalgias, arthralgias, fatigue, and a petechial rash, and is associated with travel to endemic regions. The rash usually develops two to four days after onset of fever,⁶ and typically appears as small, blanching, pink macules measuring 1 to 4 mm in diameter, initially on the ankles and wrists. The rash spreads centrally to the palms and soles, sparing the face, and evolves into macules, papules, and petechiae. Ultimately, the rash will coalesce into large ecchymoses and ulcerations.⁷

Address correspondence to A.S. Pillai, DO, FAAFP, at ASpillai@tmhs.org. Reprints are not available from the authors.

Author disclosure: No relevant financial affiliations to disclose.

REFERENCES

- Ng JJ, Jeremiah J. Hand foot mouth disease. In: Ferri FF, ed. *Ferri's Clinical Advisor 2012: Instant Diagnosis and Treatment*. St. Louis, Mo.: Elsevier Mosby; 2011:426.
- Usatine RP, Tinitigan R. Nongenital herpes simplex virus. *Am Fam Physician*. 2010;82(9):1075-1082.
- Scully C. Aphthous ulceration. *N Engl J Med*. 2006;355(2):165-172.
- Gonsalves WC, Chi AC, Nelville BW. Common oral lesions: part 1. Superficial mucosal lesions. *Am Fam Physician*. 2007;75(4):501-507.
- Rotbart HA, Hayden FG. Picornavirus infections: a primer for the practitioner. *Arch Fam Med*. 2000;9(9):913-920.
- Chapman AS, Bakken JS, Folk SM, et al.; Tickborne Rickettsial Diseases Working Group; CDC. Diagnosis and management of tickborne rickettsial diseases: Rocky Mountain spotted fever, ehrlichiosis, and anaplasmosis—United States: a practical guide for physicians and other health-care and public health professionals. *MMWR Recomm Rep*. 2006;55(RR-4):1-27.
- Bratton RL, Corey R. Tick-borne disease. *Am Fam Physician*. 2005;71(12):2323-2330. ■