

# Photo Quiz

## Progressive Rash Involving the Hands and Feet

Kelly L. Hughes, MD, Navy Operational Support Center, Fort Dix, New Jersey

Andy Chern, MD, MPH, Uniformed Services University of the Health Sciences, Bethesda, Maryland

FIGURE 1

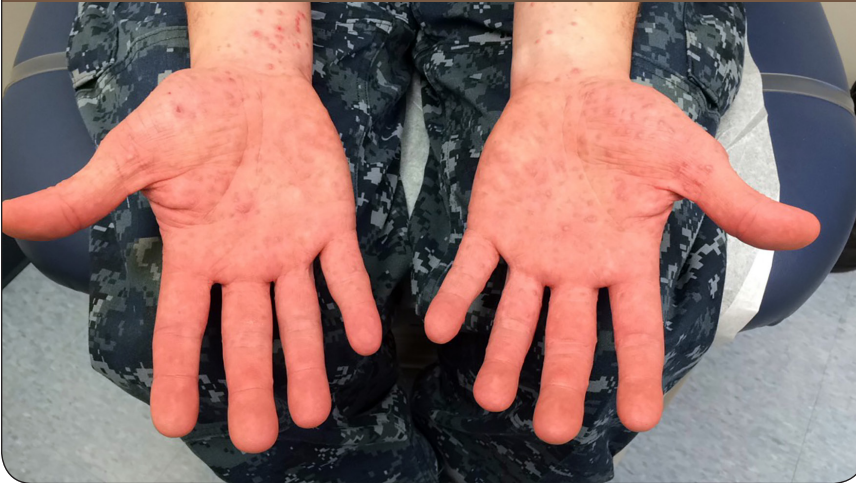
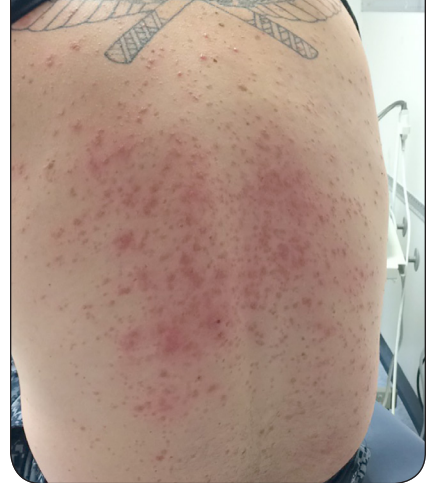
FIGURE 2



**An otherwise healthy** 34-year-old man presented in late fall with a progressive rash that started four days earlier on his hands and then spread to his arms, back, chest, and feet. The rash was mildly pruritic but nontender. He had gingival soreness. He had a mild upper respiratory tract infection one week prior that resolved. He had no recent changes in detergents, soaps, or shampoos. He had no constitutional symptoms.

He went hiking in Pennsylvania five days before the rash appeared, but he did not report any insect bites and had not traveled outside the United States. The patient had one long-term sex partner and no other sexual contacts or history of sexually transmitted infections.

On physical examination, the patient was afebrile. He had multiple blanching, erythematous papules and vesicles on his hands (*Figure 1*), chest, back (*Figure 2*), and feet. A swollen, tender left inguinal lymph node was noted. There were no oral lesions.

### Question

Based on the patient's history and physical examination findings, which one of the following is the most likely diagnosis?

- ☐ A. Coxsackie virus infection.
- ☐ B. Herpes simplex virus infection.
- ☐ C. Measles.
- ☐ D. *Rickettsia rickettsii* infection.
- ☐ E. *Treponema pallidum* infection.

See the following page for discussion.

**The editors** of *AFP* welcome submissions for Photo Quiz. Guidelines for preparing and submitting a Photo Quiz manuscript can be found in the Authors' Guide at <https://www.aafp.org/afp/photoquizinfo>. To be considered for publication, submissions must meet these guidelines. E-mail submissions to [afpphoto@aaafp.org](mailto:afpphoto@aaafp.org).

**This series** is coordinated by John E. Delzell Jr., MD, MSPH, Associate Medical Editor.

**A collection** of Photo Quiz published in *AFP* is available at <https://www.aafp.org/afp/photoquiz>.

**Previously published** Photo Quizzes are now featured in a mobile app. Get more information at <https://www.aafp.org/afp/apps>.

**Author disclosure:** No relevant financial affiliations.

## PHOTO QUIZ

### Discussion

The answer is D: *Rickettsia rickettsii* infection. *R. rickettsii* is a gram-negative bacterium that causes Rocky Mountain spotted fever. It is transmitted from the bites of various tick species, but one-third of patients with the infection do not report tick bites. Five states (North Carolina, South Carolina, Tennessee, Oklahoma, and Arkansas) account for more than 60% of spotted rickettsial disease cases in the United States.<sup>1</sup>

Rickettsial disease presents as fever, headaches, myalgias, and gastrointestinal symptoms within two weeks after a tick bite followed by the classic rash, which is characterized by erythematous macules that start around the wrists and ankles and spread across the body. The rash includes papular lesions on the palms and soles but spares the face. However, the rash does not develop in up to 12% of patients.<sup>2</sup> In severe cases, a petechial rash can result from the disseminated infection affecting endothelial cells, leading to increased vascular permeability.

Because of the delayed development of serologic markers, antirickettsial agents should be

started empirically based on clinical suspicion.<sup>3</sup> Rocky Mountain spotted fever can lead to thrombocytopenia, hyponatremia, and elevated liver transaminase levels.

Coxsackie virus is a human enterovirus that can cause hand-foot-and-mouth disease. Although it usually affects children two to 10 years of age, it may also occur in adults.<sup>4</sup> Coxsackie virus infection presents as fever and sore mouth progressing to oral lesions, as well as vesicular eruptions and erythematous papules on the palms and soles, and possibly the buttocks and perineum. The diagnosis is typically clinical.

Herpes simplex virus infection is the most common trigger of erythema multiforme.<sup>3</sup> Erythema multiforme is an immune-mediated condition characterized by the abrupt onset of erythematous macules that progress to papules and then target lesions. The rash typically favors the face and distal extremities, particularly the dorsal hands and forearms. The rash fully develops within 72 hours and resolves within two weeks.<sup>4</sup> Painful vesiculobullous lesions of the mucosa may also be present.

### SUMMARY TABLE

Infection	Condition	Characteristics	Rash
Coxsackie virus	Hand-foot-and-mouth disease	Oral lesions on the tongue, buccal mucosa, palate, uvula, and tonsillar pillars	Vesicular eruptions and erythematous macules on the palms and soles but may also affect buttocks and perineum
Herpes simplex virus	Erythema multiforme	Immune-mediated condition characterized by the abrupt onset of rash	Erythematous macules that progress to papules and then target lesions; favors the face and distal extremities; painful vesiculobullous lesions of the mucosa may be present
Measles virus	Measles (rubeola)	Prodrome of fever, cough, nasal congestion and rhinoconjunctivitis; Koplik spots (gray-white papules on the buccal mucosa) are pathognomonic	Erythematous macules and papules spreading from the trunk to the extremities
<i>Rickettsia rickettsii</i>	Rocky Mountain spotted fever	Fever, headaches, myalgias, and gastrointestinal symptoms	Erythematous macules that start around the wrist and ankles and spread across the body but spare the face; papular lesions on the palms and soles
<i>Treponema pallidum</i>	Secondary syphilis	Presents up to six months after primary lesion if left untreated; low-grade fever, malaise, sore throat, adenopathy, and myalgias	Generalized maculopapular eruption involving the face, trunk, extremities, palms, and soles; may involve mucous membranes and develop patchy alopecia

## PHOTO QUIZ

Measles (rubeola), caused by a paramyxovirus, is highly contagious through respiratory spread. It leads to a prodrome of fever, cough, nasal congestion, and rhinoconjunctivitis. The exanthema is a morbilliform eruption, including erythematous macules and papules, that starts on the trunk and spreads to the extremities. Koplik spots (gray-white papules on the buccal mucosa) are pathognomonic. Serologic testing can confirm the diagnosis. Vaccination for measles is 99% effective.<sup>5</sup>

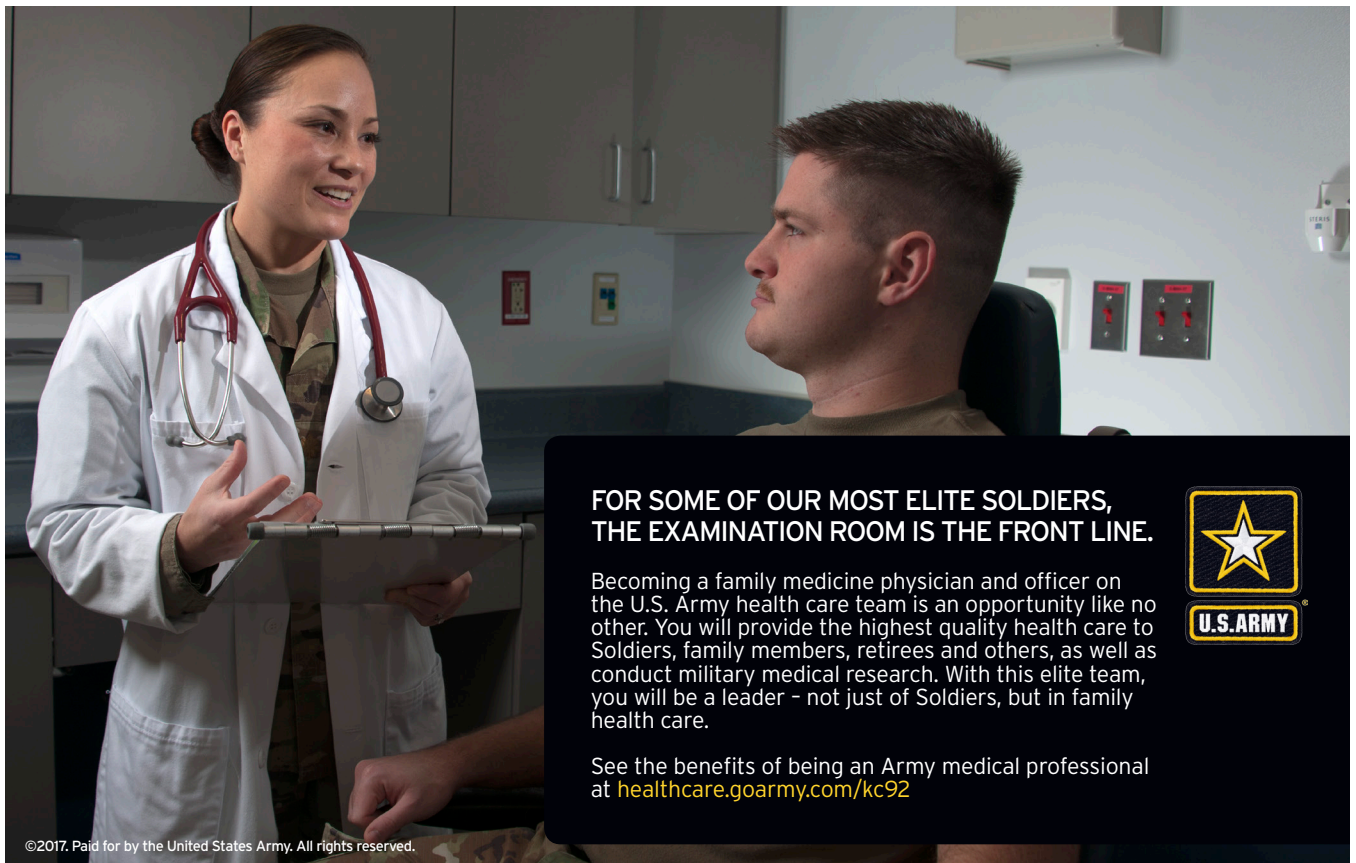
*Treponema pallidum* is a sexually transmitted spirochete bacterium that causes syphilis. If left untreated, the disease progresses through three stages. In secondary syphilis, constitutional symptoms, such as low-grade fever, malaise, sore throat, adenopathy, and myalgias, may occur with a generalized maculopapular eruption involving the face, trunk, extremities, palms, and soles.<sup>4</sup>

**Address correspondence** to Andy Chern, MD, MPH, at [andy.chern@usuhs.edu](mailto:andy.chern@usuhs.edu). Reprints are not available from the authors.

**The opinions** and assertions contained herein are the private views of the authors and are not to be construed as official or as reflecting the views of the Department of the Navy, Department of the Army, Department of Defense, or the U.S. government.

## References


1. Centers for Disease Control and Prevention. Rocky Mountain spotted fever (RMSF). <https://www.cdc.gov/rmsf/index.html>. Accessed July 11, 2017.
2. Dantas-Torres F. Rocky Mountain spotted fever. *Lancet Infect Dis*. 2007;7(11):724-732.
3. Bologna J. *Dermatology*. 3rd ed. Philadelphia, Pa.: Elsevier Saunders; 2012.
4. James WD, Berger TG, Elston DM. *Andrews' Diseases of the Skin: Clinical Dermatology*. 12th ed. Philadelphia, Pa.: Elsevier; 2016.
5. Watson JC, Hadler SC, Dykewicz CA, Reef S, Phillips L. Measles, mumps, and rubella—vaccine use and strategies for elimination of measles, rubella, and congenital rubella syndrome and control of mumps: recommendations of the Advisory Committee on Immunization Practices (ACIP). *MMWR Recomm Rep*. 1998;47(RR-8):1-57. ■



**FOR SOME OF OUR MOST ELITE SOLDIERS, THE EXAMINATION ROOM IS THE FRONT LINE.**

Becoming a family medicine physician and officer on the U.S. Army health care team is an opportunity like no other. You will provide the highest quality health care to Soldiers, family members, retirees and others, as well as conduct military medical research. With this elite team, you will be a leader – not just of Soldiers, but in family health care.

See the benefits of being an Army medical professional at [healthcare.goarmy.com/kc92](http://healthcare.goarmy.com/kc92)



©2017. Paid for by the United States Army. All rights reserved.